

Ameliorative effect of *Ficus dalhousiae* Miq. (Moraceae) methanolic leaf extract on carbon tetrachloride induced hepatic and renal toxicity

Swati Kujur¹, Sunil Kumar CR¹, Anand Barapatre², Geetha N^{1*}

*Corresponding author:

Geetha N

¹Department of Studies in Biotechnology, University of Mysuru, Mysuru, Karnataka, INDIA 570006.

²Department of Biotechnology, Guru Ghasidas Vishwavidyalaya, Bilaspur, Chhattisgarh, INDIA- 495009.

Abstract

Developing traditional medicine in the field of hepatology and nephrology research is the key to pharmacology. This study demonstrates the mechanism of hepatoprotective and renal protective activity of *Ficus dalhousiae* Miq. (Moraceae) methanolic leaf extract on carbon tetrachloride induced hepatic and renal toxicity. Shade dried powder was subjected to Soxhlet extraction with methanol and assessed for hepatoprotective and renal protective activities. Hepatotoxicity and renal toxicity were induced in rats by single oral dose of CCl₄ diluted with olive oil (1:1 v/v; ml/kg body weight) after pretreatment of methanolic extract for seven days. Sixteen hrs after CCl₄ administration, rats were sacrificed and biochemical markers like Serum alanine aminotransferase (ALT), aspartate aminotransferase (AST), alkaline phosphatase (ALP) and lactate dehydrogenase (LDH) estimated followed by the measurement of liver and kidney cytosolic antioxidant enzymes such as superoxide dismutase (SOD), catalase (CAT), glutathione (GSH) and reactive oxygen species (ROS). The data were analysed by one way analysis of variance (ANOVA). The extract at the doses of 150 and mg/kg b.w. significantly reduces elevated levels of ALT, AST, ALP and LDH. The extracts also showed significant increase in the reduced level of SOD, CAT and GSH. The ROS activity also found down regulated. The activity of methanolic extracts were comparable with the standard Silymarin. These findings not only showed potential hepatoprotective and renal protective activities of *Ficus dalhousiae* but also manifested by restoring antioxidant enzymes. With this pilot study we can justify the medicinal importance of this plant.

Keywords: superoxide dismutase, catalase, glutathione and reactive oxygen species.

Introduction

There are various organic compounds, environmental pollutants and drugs which causes cellular damage. Carbon tetrachloride (CCl₄) is a potent environmental hepatotoxins [1-4]. In addition to hepatic problems, CCl₄ also causes disorder in kidneys, lungs, testis and brain as well as in blood by generating free radicals [5-8]. Reactive oxygen species (ROS) are chemically reactive molecules containing oxygen and are formed as a natural byproduct of the normal metabolism of oxygen and have important roles in cell signaling and homeostasis [9]. This may result in significant damage to cell structures. Cumulatively, this is known as oxidative stress. Studies also revealed that there are various herbal extracts could protect organ against CCl₄ induced oxidative stress by enhancing the decreased level of catalase (CAT), superoxidase dismutase (SOD), reduce glutathione (GSH) [10,11] and also decrease the level of ROS.

Natural plant products have been widely used for medical purpose and according to Ayurveda, these medicine have less side effect when compared with allopathy medicine. In Ayurveda, plants are widely used for medicinal purpose. Compare with allopathy

medicine it have less side effects or no side effects. *Ficus dalhousiae* Miq belong to family Moraceae, which is reported to have various medicinal properties like in the treatment of liver, skin diseases [12] and its root possesses very good anti-inflammatory activity [13]. The present study was undertaken to evaluate protective effect of *Ficus dalhousiae* leaf bark extracts on CCl₄ induced toxicity in rat liver and kidney.

Materials and method

Materials

Chemicals

Dichlorofluorescein diacetate (DCF-DA), thiobarbituric acid (TBA), glutathione, bovine serum albumin (BSA), 5,5-dithiobis (2-nitrobenzoic acid) (DTNB), 2,4-dinitrophenyl hydrazine (DNPH) were purchased from Sigma-Aldrich Inc. (Mumbai, India) trichloroacetic acid (TCA), hydrogen peroxide (H₂O₂; 30%),

DOI:10.5138/09750185.1992



This article is distributed under the terms of the [Creative Commons Attribution License](https://creativecommons.org/licenses/by/4.0/), which permits unrestricted use and redistribution provided that the original author and source are credited.

thiobarbituric acid (TBA), sodium citrate, pyrogallol, and ethylene diamine tetra acetic acid (EDTA) and other chemicals and solvents used were purchased from various suppliers with highest purity grade.

Plant material

The fresh leaves of *Ficus dalhousiae* were collected from KBF-1001, 01.xi.2008, hill top of Kunthi Betta (12.50 N & 76.69 E), near Pandavapura (Mandya District), Karnataka (India) [14] and authenticated by Dr. K. K. Sampath. The leaves were washed under running tap water followed by distilled water, shade dried and coarsely powdered.

Extraction procedure and conditions

Thirty grams of the powdered leaf samples were extracted using methanol by soxhlet apparatus. The solid to liquid ratio was kept at 1:10 and the process was run for a total of 16 hours. After extraction, the resultant extracts were allowed to concentrate to dryness under reduced pressure in a rotary evaporator (Heidolph rotary evaporator) to yield methanolic extract (FdLM) and dried material were kept in air tight tubes in dark at 4 °C.

Animal and Treatments

For *in vivo* studies, 8 week old, adult male Wistar albino rats (150-200 g) were obtained from Central Animal House Facility, Department of Science in Zoology, University of Mysuru (UOM), Karnataka, INDIA. The rats were kept in separated animal rooms with a 12 h light-dark cycle, and the temperature and humidity were kept at 23 ± 2 °C and 55%-65%, respectively. The animal care and experimental procedures performed were in compliance with the Regulations for Animal Research and Animal Ethical Committee of the UOM. Rats were acclimatized for a week and randomly divided into five groups (n = 6, per group).

FdLM extracts were dissolved in sterile distilled water and two different concentrations were administered orally. The scheme of the treatment was as follows:

Group I - (normal control) received neither plant extract nor CCl₄ but they received only food and water.

Group II – serve as a toxic control and received CCl₄ (1 mg/ml); only once on 8th day.

Group III – FdLM (150 mg/kg b.w.) followed by CCl₄ (1 mg/ml); only once on 8th day.

Group IV – FdLM (300 mg/kg b.w.) followed by CCl₄ (1 mg/ml); only once on 8th day.

Group V– Silymarin (100 mg/kg b.w.) followed by CCl₄ (1 mg/ml); only once on 8th day.

On the eighth day, the rats of Group II to V were administered a single oral dose of CCl₄ in olive oil (1:1) at 1 ml of body weight after

the last dose of extracts. Sixteen hours after CCl₄ administration, animals were sacrificed by anaesthesia. The liver was perfused with saline and processed immediately for biochemical assay.

Estimation of Serum enzymes

Blood samples were collected through retro-orbital plexus and allowed to clot for 30 min at 28 °C. The serum was collected by centrifugation for 10 min at 2,000 rpm and stored at 4 °C. Liver damage was assessed by estimating serum activities of alanine aminotransferase (ALT), aspartate aminotransferase (AST), alkaline phosphatase (ALP) and lactate dehydrogenase (LDH) using commercially available test kits. The results were expressed as units/liter (U/L).

Assessment of GSH

The level of reduced Gultathione (GSH) in the liver and kidney was measured [15]. The Liver and kidney tissue (0.5 g) was homogenized in 5 ml of 1:1 cold buffer (10% TCA, 10 mM EDTA, pH 7.4) at 4 °C. The homogenate was centrifuged at 5,000 rpm for 10 min at 4 °C and the supernatant was used for the determination of GSH level. A 100 µl of supernatant was added to 3.0 ml of 0.2 M Tris-HCl and 50 µl of Ellman's reagent (0.02% of DTNB). Blank was without DTNP. The yellow colour developed was measured immediately at 412 nm.

Assessment of Catalase activity

Assessment of catalase activity in liver and kidney was according to the method [16] and [17]. Liver and kidney tissue was homogenized (10% w/v) in ice cold 50 mM phosphate buffer (pH 7.4), centrifuged at 2,500 rpm for 10 min at 4 °C and the supernatant was used for determining catalase activity. The activity was measured using 3% H₂O₂ (v/v) as the substrate in phosphate buffer and the change in absorbance was measured at 240 nm for two min at 30 s intervals. Units of catalase were expressed as the amount of enzyme that decomposes 1 µM of H₂O₂ per min at 25 °C and the activity was expressed as units/mg of protein.

Assessment of superoxide (SOD) activity

For the assessment of SOD activity liver and kidney tissue was homogenized (10% w/v) in ice cold 50 mM phosphate buffer (pH 7.4), centrifuged at 2500 rpm for 10 min at 4 °C and the supernatant was used for assessing SOD activity. The activity was measured using pyrogallol (2 mM) auto oxidation in Tris buffer (pH 8.2). The reaction mixture contained 0.1 Tris buffer and tissue homogenate. Reaction was started by adding 2 mM pyrogallol. The absorbance was read at 420 nm for two min at an interval of 30 s Involvement of the superoxide anion radical in the autoxidation of pyrogallol and a

convenient assay for superoxide dismutase. European Journal of Biochemistry Involvement of the superoxide anion radical in the autoxidation of pyrogallol and a convenient assay for superoxide dismutase. European Journal of Biochemistry [18].

Reactive oxygen species (ROS) assay

The ROS activity was measured by the fluorometric assay by the use of DCF-DA reagent [19]. Liver and kidney tissue was homogenized (10% w/v) in ice-cold 50 mM phosphate buffer (pH 7.4), centrifuged at 5,000 g for 10 min at 4 °C. Supernatant was used to measure relative fluorescence unit in a fluorescence spectrophotometer at the excitation and emission wavelengths of 488 and 525 nm, respectively.

Histopathological studies of liver tissues

For histopathological examination, a small portion of liver and kidney was transferred to 4% formalin solution (v/v) for fixation and later on processed [20]. The microtome sections were cut, processed and stained with hematoxylin and eosin. The sections of liver and kidney of both control and treated rats were scanned and analysed by Carl-Zeiss microscope (Axio Imager 2).

Functional group characterization of FdLM by FTIR

FTIR analysis was performed to detect the characteristic functional groups in the FdLM using FTIR spectrophotometer (Perkin Elmer, Version 10.03.09). Dry fraction of the sample (FdLM) was ground properly with spectrophotometric grade KBr (1:100) and spectrum was obtained in the range of 600–4000 cm^{-1} .

Statistical Analysis

Proper evaluations were performed by using SPSS 22 software in which multiple groups were analysed by one way analysis of variance (ANOVA). The experiments were carried out in triplicates and presented as mean \pm SD and the significance was considered at $p < 0.05$. IC_{50} values were calculated from logarithmic dose response curve by the use of Graphpad Prism 5.0.

Results and Discussion

Many previous reports demonstrate that carbon tetrachloride (CCl_4), is a typical hepatotoxic compound and it causes significant damage to the liver after a single intraperitoneal dose [3,21]. Generation of free radical reactions is the main reason of the CCl_4 mediated liver injury, which produced during its metabolism inside the liver. This free radical is another outcome in the form of the initiation of lipid per oxidation [22].

Serum Enzyme

The effect of *F. dalhousiea* bark extract (FdLM) on serum AST, ALT, ALP, and LDH levels in treated wistar rats along with the control rats presented in Table.1. The increase levels of AST, ALT, ALP and LDH in CCl_4 treated group serum as compared to the control normal group clearly indicated the toxicity of the CCl_4 and the level of increment of the above marker enzymes in CCl_4 intoxicated rats were 2.06, 3.83, 1.97 and 1.71 time respectively. After administration of extract to the CCl_4 intoxicated rats, the levels of AST, ALT, ALP and LDH were significantly ($p < 0.05$) reduced as compared to the CCl_4 toxic control groups. The reduction in the level of enzyme was significantly high in group IV (FdLM 300 mg) as compared to group III (FdLM 150 mg). The standard drug Silymarin (300 mg) also produced almost the similar results when the CCl_4 intoxicated rats were treated with equal amount of FdLM (300 mg, group IV) indicating that the FdLM extract was almost equally effective in the reduction of CCl_4 induced toxicity.

Table-1: Protective effect of *F. dalhousiea* bark extract (FdLM), pre-treatment on CCl_4 intoxicated rats.

S.No	Groups	AST (U/L)	ALT (U/L)	ALP (U/L)	LDH (U/L)
1.	Control	91.25 \pm 1.13 ^d	36.34 \pm 0.75 ^d	127.75 \pm 4.30 ^d	1261.95 \pm 26.11 ^d
2.	CCl_4	188.86 \pm 2.45 ^a	139.34 \pm 1.74 ^a	251.92 \pm 3.42 ^a	2518.80 \pm 79.57 ^a
3.	FdLM (150 mg) + CCl_4	149.45 \pm 8.48 ^b	84.66 \pm 1.72 ^b	164.61 \pm 5.83 ^b	1700.73 \pm 40.86 ^b
4.	FdLM (300 mg) + CCl_4	113.24 \pm 3.13 ^c	57.52 \pm 3.44 ^c	149.58 \pm 2.24 ^{b,c}	1483.45 \pm 27.87 ^c
5.	Silymarin (300 mg) + CCl_4	106.45 \pm 4.17 ^{c,d}	48.63 \pm 1.00 ^c	141.96 \pm 1.40 ^{c,d}	1359.53 \pm 6.87 ^{c,d}

Data with different letters in the same column are significantly different at $p < 0.05$.

Effect of FdLM treatment on rat liver and kidney antioxidant enzymes in CCl_4 intoxicated rats

The effect of *F. dalhousiea* bark extract (FdLM) pre-treatment on liver antioxidant enzymes (GSH, SOD and CAT) in CCl_4 intoxicated rats are presented in Figure. 1-3. It was found that in control group all three enzyme activities were high from other groups.

The quantity of GSH enzyme in control rat liver (group - I) was found 0.99 ± 0.02 $\mu\text{g}/\text{mg}$ protein, while in the CCl_4 intoxicated rat the production was 4.3 fold lower i.e. 0.23 ± 0.04 . On the other hand, in the FdLM and the control drug supplemented group (Silymarin), GSH activity was recovered after the CCl_4 intoxication. In the group where 300 mg FdLM (group IV) was supplemented, display a better GSH activity (0.77 ± 0.02 $\mu\text{g}/\text{mg}$) compared to

positive control drug (group V; 0.74 ± 0.09 $\mu\text{g}/\text{mg}$), and activity was recovered up to ~71% when compared to CCl_4 intoxicated rat, while rat supplemented with 150 mg FdLM (group III) had recovered GSH activity in significantly lower level i.e. only ~26% (0.43 ± 0.04 $\mu\text{g}/\text{mg}$).

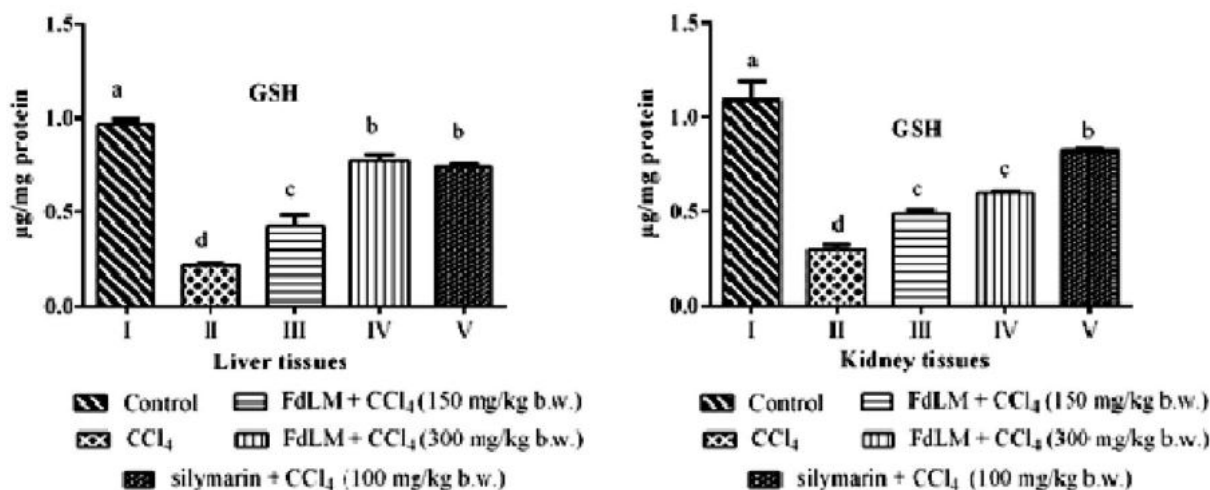


Figure 1: GSH activity in the rat liver and kidney tissues before and after CCl_4 intoxicated. Group I – control; Group II – CCl_4 ; Group III– FdBL 150 mg/kg b.w. + CCl_4 ; Group IV– FdBL 300 mg/kg b.w. + CCl_4 ; Group V – silymarin 100 mg/kg b.w. + CCl_4 . Each bar represents the mean \pm SE, $n = 6$; bars with different alphabets differ significantly at $p < 0.05$ level.

In the case of rat kidney the GSH level was highest 1.09 ± 0.07 $\mu\text{g}/\text{mg}$ in the control rats, The intoxication of CCl_4 produce a considerable inhibition effect on the production of GSH and among all tested rats the GSH level was found significantly lower (0.29 ± 0.01 $\mu\text{g}/\text{mg}$) in CCl_4 intoxicated rats. The treatment of CCl_4 intoxicated rats with FdLM produce slightly lower recovery of GSH production in kidney tissue compared to liver tissue. The highest GSH activity was recovered in case of the drug Silymarin (100 mg/kg b.w.) and it was ~75.23% (0.82 ± 0.05 $\mu\text{g}/\text{mg}$) after the CCl_4 intoxication in comparison to control, whereas the rats treated with test samples recovered about ~44.03 and 55.05% GSH activity for 150 and 300 FdLM mg/kg b.w.

Superoxide dismutase (SOD) activity in liver and kidney tissues of control and CCl_4 intoxicated rats is shown in Figure. 2. In the liver tissue, there was a huge difference in the SOD activity in control and CCl_4 intoxicated rat which was 2.95 ± 0.16 and 0.12 ± 0.01 IU/mg protein respectively (Figure. 2A). CCl_4 almost ceased the SOD activity and produced oxidative stress conditions. In the CCl_4 intoxicated rat, it was observed that the SOD activity dropped upto ~93%. The treatment of CCl_4 intoxicated rat with FdLM and silymarin recover the SOD activity and helped in the reduction in oxidative stress mediated damage. The highest recovery of SOD activity was found in the case of Silymarin drug (group - V) where

the activity was found 78.31% of control. The treatment of CCl_4 intoxicated rat with FdLM recovered 56.27% and 65.08% SOD activity respectively for 150 and 300 mg/kg b.w. FdLM. It was observed that the high dose of FdLM (300 mg/kg b.w.) was more effective than lower dose.

In rat kidney tissue, the SOD activity drastically decreased after intoxication with CCl_4 (Figure. 2B) and the significant reduction was observed after 8th day of CCl_4 intoxication, from 2.11 ± 0.14 to 0.37 ± 0.05 units/mg protein. Among all the three treated groups, the group - V in which Silymarin drug treated CCl_4 intoxicated rat shows the highest recovery for SOD activity, and it shows about 84.36% activity (1.78 ± 0.03 units/mg protein) compared to the control. In comparison to liver tissue, the recovery of SOD activity in kidney was less and it was obtained about 0.84 ± 0.1 and 1.07 ± 0.09 units/mg protein which is about 39.81 and 50.71% compared to control.

In the case of CAT activity, there was a drastically different pattern was obtained in the rat liver and kidney tissues. In the control rat (group - 1), the CAT activity in liver and kidney tissue was found to 4.06 ± 0.03 and 2.10 ± 0.056 IU/ml respectively, while in CCl_4 intoxicated rats the reduction in the CAT was 27.34 (1.11 ± 0.05 IU/ml) and 18.09% (0.38 ± 0.05 IU/ml) in liver and kidney tissue respectively. In FdLM treated rat liver the CAT activity was high in

group IV (treatment with 300 mg/kg d.w. FdLM) whereas in case of kidney tissue, higher activity about ~91% (1.91 ± 0.08 IU/ml).was in

group III (treatment with 150 mg/kg d.w. FdLM).

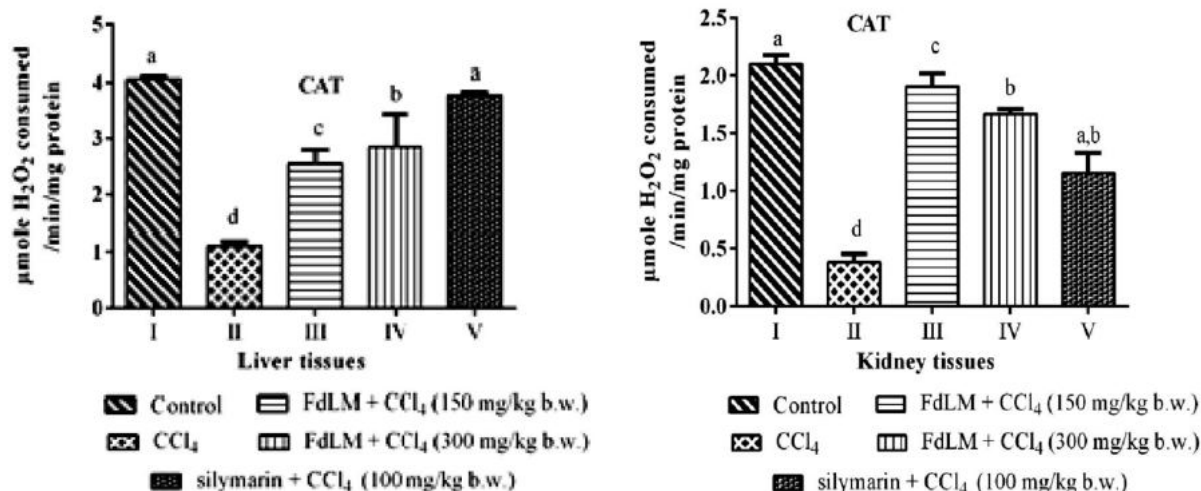


Figure. 2: SOD activity in the rat liver and kidney tissue before and after, CCl₄ intoxication. Group I – control; Group II – CCl₄; Group III– FdBL 150 mg/kg b.w. + CCl₄; Group IV– FdBL 300 mg/kg b.w. + CCl₄; Group V – silymarin 100 mg/kg b.w. + CCl₄. Each bar represents the mean ± SE, n = 6; bars with different alphabets differ significantly at $p < 0.05$ level.

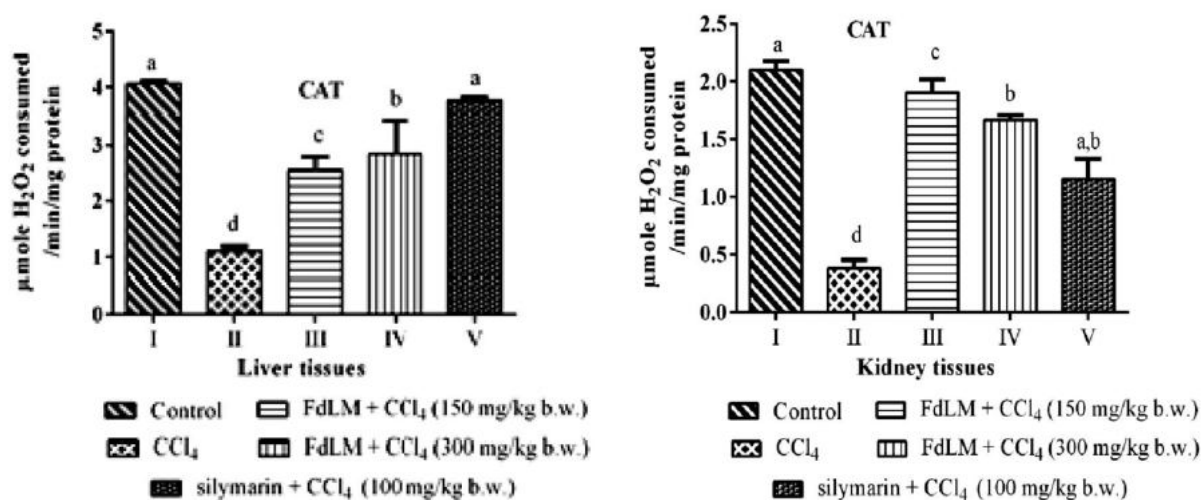


Figure. 3: Catalase (CAT) activity in the rat liver and kidney tissues before and after, CCl₄ intoxication. Group I – control; Group II – CCl₄; Group III– FdBL 150 mg/kg b.w. + CCl₄; Group IV– FdBL 300 mg/kg b.w. + CCl₄; Group V – Silymarin 100 mg/kg b.w. + CCl₄. Each bar represents the mean ± SE, n = 6; bars with different alphabets differ significantly at $p < 0.05$ level.

Reactive oxygen species (ROS) assay

Reactive oxygen species (ROS) activity in liver and kidney tissues of control and CCl₄ intoxicated rats is shown in Figure. 4. The

activity of ROS is induced in the group –II, Which was treated only with CCl₄ in both kidney and liver tissues. But prior treatment with FdLM extracts down- regulated the activity of ROS with the concentration of 150 mg/kg b.w. and 300 mg/kg b.w.

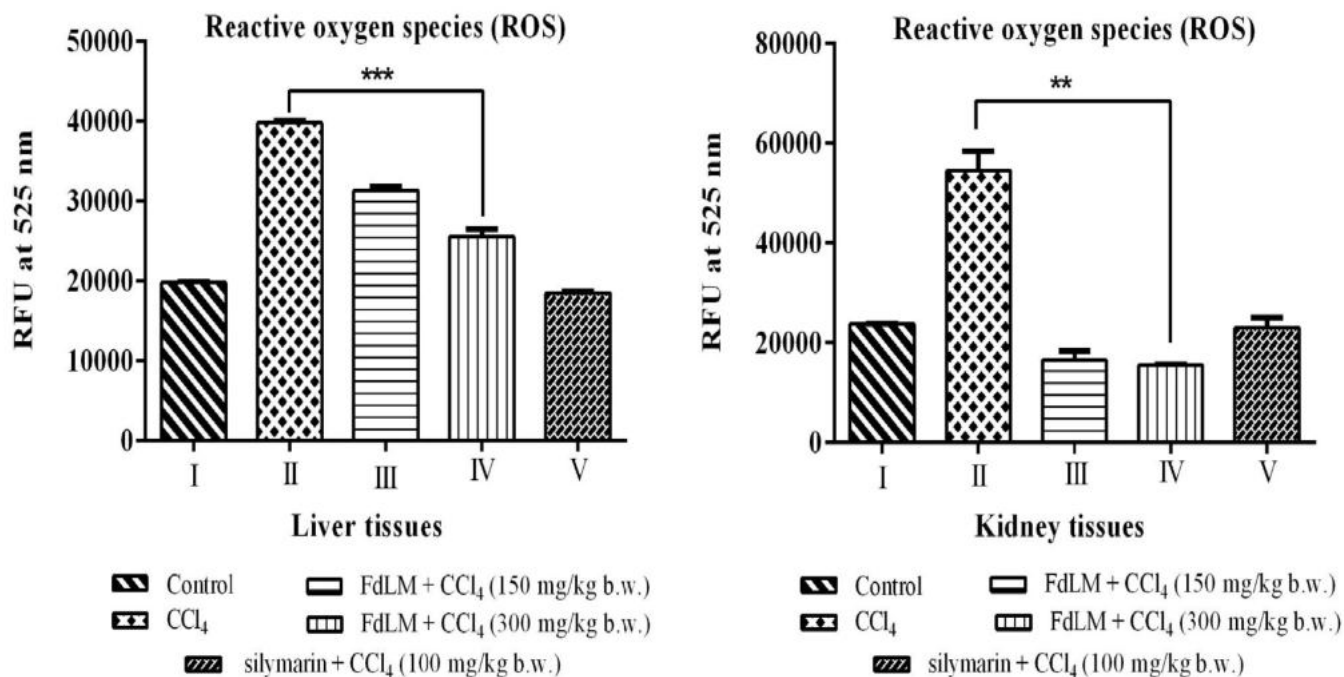


Figure.4: Amelioration of oxidative stress by the leaf methanolic extract of *F. dalhousiae* in the rat liver and kidney tissues caused by, reactive oxygen species (ROS). Group I – control; Group II – CCl₄; Group III– FdLM 150 mg/kg b.w. + CCl₄; Group IV– FdLM 300 mg/kg b.w. + CCl₄; Group VII – Silymarin 100 mg/kg b.w. + CCl₄. Each bar represents the mean \pm SD, n = 6; bars with different alphabets differ significantly at $p < 0.05$ level.

Histopathology

Kidney

The histological study of the kidney tissue sections of the control group rats (Groups I) did not show any abnormal microscopic findings. The variations in kidney section of CCl₄ intoxicant rat (Fig. 5B) displayed the major signs of extensive tubular necrosis (blue arrow) along with the high degree loss of their brush border (black arrow), with less intact renal tubules (yellow arrow), many cast formation (black asterisk), tubular dilation (green arrow) and a thickened basement membrane. An increased sized Bowman's capsules were occupying the whole glomeruli spaces. The epithelial lining cells were found highly disrupted with pyknotic nuclei. Hemorrhage and lymphocytic infiltrate in the interstitial area and periglomerular lymphocytic infiltration were noticed. Some of

the tubules having protein casts. A segmental sclerosis with basement membrane thickening and interstitial fibrosis was found in CCl₄ intoxicated kidney but most of the glomeruli showed atrophy.

These changes were found to be significantly reduced in kidneys of the experimental group treated with extract. The group of rats which received lower dosages of extract (150 mg/kg) showed moderate improvement in the tubular and glomerular morphology. Post treatment with the plant extract at 300 mg/kg dose showed considerable improvement in glomeruli and tubules. Bowman's capsule showed comparatively less hypertrophy. Glomeruli were compact with wide spacing in the Bowman's capsule. Tubules were organized but debris was seen. Lumens were maintained. Epithelium was intact in most of the tubules and hence improved histoarchitecture of the kidney (Figure. 6). The thickening of the walls was decreased by the extract (150 and 300 mg/kg) treatment (Figure. 6).

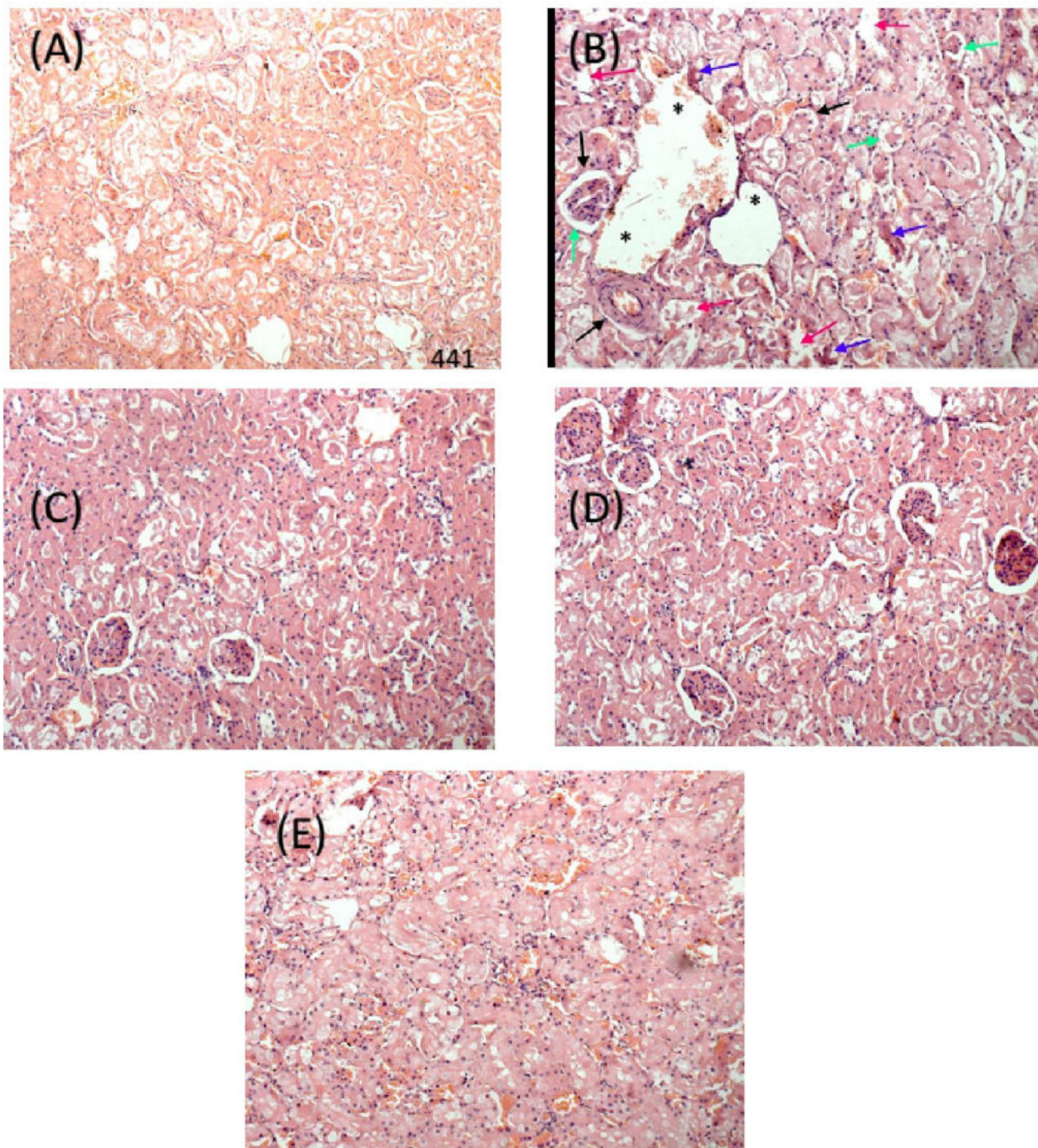


Figure.5: Representative histopathological sections of kidney of wistar rats stained with hematoxylin and eosin under the influence of *F. dalhousiea* bark extract (FdLM) A: Group I – control; B: Group II – CCl₄; C: Group III– FdLM 150 mg/kg b.w. + CCl₄; D: Group IV– FdLM 300 mg/kg b.w. + CCl₄; E: Group VII – Silymarin 100 mg/kg b.w. + CCl₄.

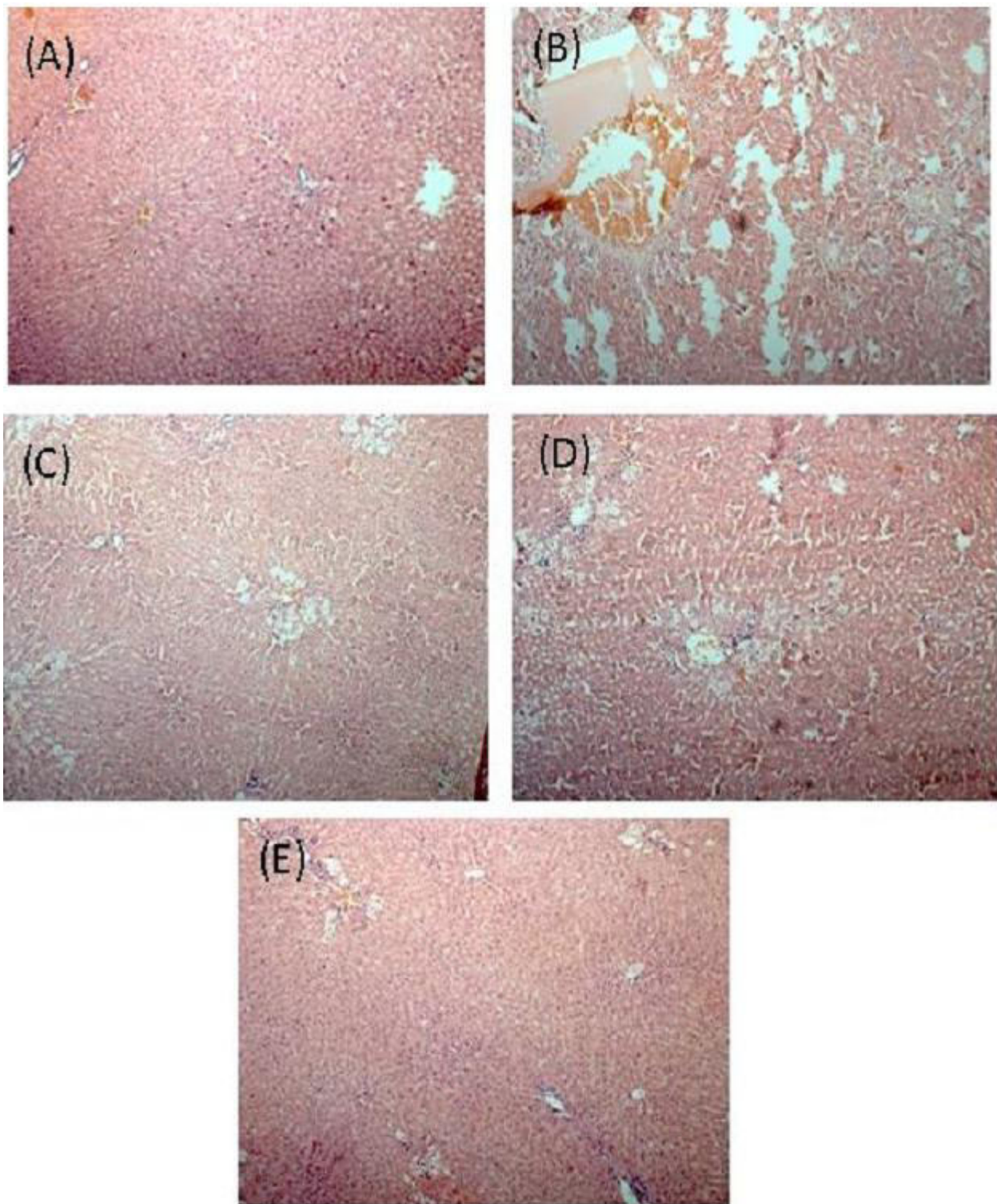


Figure.6: Effect of *F. dalhousiea* bark extract (FdLM) on histological profile of liver in wistar rats. Group I – control; Group II – CCl₄; Group III– FdLM 150 mg/kg b.w. + CCl₄; Group IV – FdLM 300 mg/kg b.w. + CCl₄; Group VII – Silymarin 100 mg/kg b.w. + CCl₄.



Liver

The histopathological section of liver from control, CCl₄ intoxicated, standard drug silymarin and extract treated rats were collected at the end of the experimental periods (i.e., 8th day after CCl₄ treatment Figure. 3). Untreated rat liver showed normal lobular architecture with intact central vein and sinusoids, normal portal tracts and preserved hepatocytes. While, CCl₄ intoxicated rats liver

tissue depicted the necrosis, surrounding fibrosis, perivenular inflammation and vacuole formation. Rats treated with the FdLM (group II and IV) and standard drug revealed the reduced vacuole formation and inflammation and almost normal hepatocellular architecture in the liver section. Overall histopathological examination showed a protective effect of FdLM on CCl₄ induced hepatotoxicity.

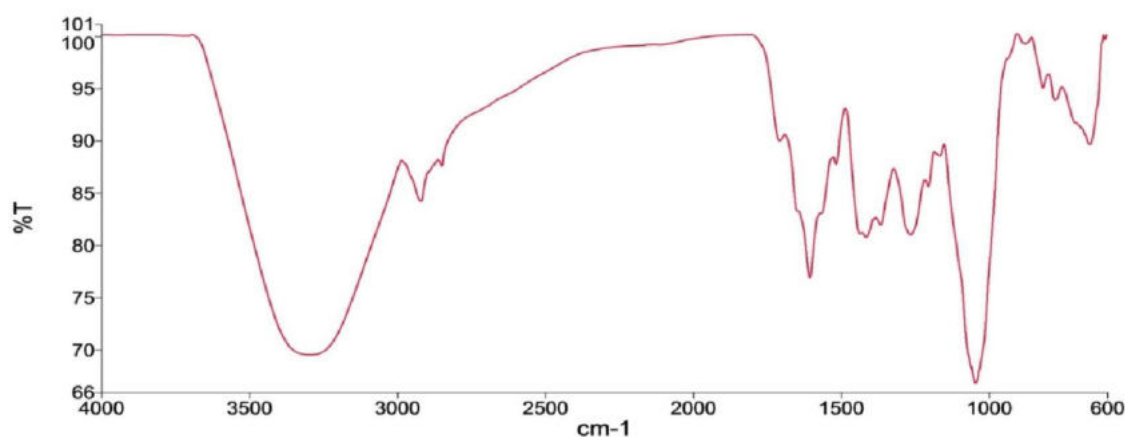


Figure. 7: FTIR spectra of methanolic extract of *F. dalhousiea* bark

Functional group characterization of methanolic extract of *F. dalhousiea* bark by FTIR

The FTIR spectrum of methanolic extract of *F. dalhousiea* bark showed a wide absorption peak band at 3410–3460 cm⁻¹, which correspond to the stretching of O–H groups in phenolic and aliphatic structures and oscillation of the hydroxyl group (23). It was reported that, the phenolic mobile hydrogen atom (Ar-OH) plays the significant role in the scavenging of reactive free radicals (like SOD and ROS) (24). Absorption peak obtained at 2938 and 2842 cm⁻¹, primarily due to the C–H stretching in aromatic methoxyl groups and in methyl and methylene groups of side chains. The characteristic vibration in aromatic ring skeleton was obtained at 1605, 1518 and 1442 and also 1360 cm⁻¹ recognized for the aromatic skeleton vibration and O-CH₃, C-H deformation symmetry. The band near 1250 and 1050 cm⁻¹ appeared mainly due to aromatic C-O, C-H and C=O out of plane deformation (23). The obtained characteristic peaks in FdLM also suggest that this fraction contains aromatic moiety having a strong free radical scavenging capacity.

Conclusion

Overall, our study concluded that *Ficus dalhousiae* Miq. (Moraceae) leaf methanolic extract prevented CCl₄ induced hepatic and renal toxicity by scavenging free radicals, which suggested that

antioxidant molecule is present in FdLM extract which accelerate the antioxidant capacity of liver and kidney.

Authors Contribution

Geetha N supervised the project, Swati Kujur performed the experiments, drafted the manuscript and interpreted the results. Sunil K.C.R. assisted in handling animals, and experiments Anand Barapatre helped in analyzing FTIR spectra. All the authors involved in drafting and revision of manuscript and approved the final manuscript.

Acknowledgement

The first author thanks Department of Biotechnology (DBT, New Delhi, India) for DBT-JRF Fellowship. We also thank sophisticated instrument facilities, University of Mysore, under the IOE (Institution of Excellence) programme by Government of India from Ministry of Human Resource Development and University Grant Commission, New Delhi, India.

Conflicts of interest

The author declares that there are no conflicts of interest.



References

- [1]. Sarkar K, Ghosh A, Kinter, M, Mazumder B, Sil PC. Purification and Characterization of a 43 kD Hepatoprotective Protein from the Herb *Cajanus indicus* L. *The Protein Journal* 2006; 25: 411-421.
- [2]. Abraham P, Wilfred G, Cathrine S. Oxidative damage to the lipids and proteins of the lungs, testis and kidney of rats during carbon tetrachloride intoxication. *Clinica Chimica Acta*. 1999; 289: 177-179.
- [3]. Szymonik-Lesiuk S, Czechowska G, Stryjecka-Zimmer M, SŁomka M, M dro A, Celi ski K, Wielosz M. Catalase, superoxide dismutase, and glutathione peroxidase activities in various rat tissues after carbon tetrachloride intoxication. *Journal of hepato-biliary-pancreatic surgery*. 2003; 10: 309-315.
- [4]. Güven A, Gülmez M. The Effect of Kefir on the Activities of GSH-Px, GST, CAT, GSH and LPO Levels in Carbon Tetrachloride-Induced Mice Tissues. *Journal of Veterinary Medicine, Series B*. 2003; 50: 412-416.
- [5]. Charbonneau M, Brodeur J, du Souich P, Plaa GL. Correlation between acetone-potentiated CCl₄-induced liver injury and blood concentrations after inhalation or oral administration. *Toxicology and applied pharmacology* 1986; 84: 286-294.
- [6]. Ahmad F, Cowan D, Sun A. Detection of free radical formation in various tissues after acute carbon tetrachloride administration in gerbil. *Life sciences*. 1987; 41: 2469-2475.
- [7]. Ohta Y, Nishida K, Sasaki E, Kongo M, Ishiguro I. Attenuation of disrupted hepatic active oxygen metabolism with the recovery of acute liver injury in rats intoxicated with carbon tetrachloride. *Research communications in molecular pathology and pharmacology*. 1997; 95: 191-207.
- [8]. Ozturk F, Ucar M, Ozturk IC, Vardi N, Batcioglu K. Carbon tetrachloride-induced nephrotoxicity and protective effect of betaine in Sprague-Dawley rats. *Urology*. 2003; 62: 353-356.
- [9]. Devasagayam T, Tilak J, Bolor K, Sane KS, Ghaskadbi SS, Lele R. Free radicals and antioxidants in human health: current status and future prospects. *Japi*. 2004; 52:4.
- [10]. Ko KM, Ip SP, Poon MKT, Wu S, Che CT, Ng KH, Kong YC. Effect of a lignan-enriched fructus schisandrae extract on hepatic glutathione status in rats: protection against carbon tetrachloride toxicity. *Planta medica*. 1995; 61: 134-137.
- [11]. Rajesh M, Latha M. Protective activity of *Glycyrrhiza glabra* Linn. on carbon tetrachloride-induced peroxidative damage. *Indian Journal of Pharmacology*. 2004; 36:284.
- [12]. Ghori SS, Khan M, Khan SA, Baig MD. Antihyperglycaemic Effect Of *Ficus dalhousiae* Miq Leaf Ethanolic Extract In Alloxan-Induced Diabetic Rats. *International Journal of Pharmacy and Pharmaceutical Sciences*. 2014; 6: 132-136.
- [13]. Ghori SS, Khan M, Tabassum R. Anti-Inflammatory activity Of *Ficus dalhousiae* Miq roots ethanolic extract in Wistar Albino rats. *Asian Journal of Pharmaceutical and Clinical Research*. 2015; 8: 117-119.
- [14]. Kumara K, Sringswara A, Sadananda K, Prakash H. New distribution record of the endemic and rare *Ficus dalhousiae* Miq. (Moraceae). *Journal of Threatened Taxa*. 2013; 5: 4808-4810.
- [15]. Ellman GL. Tissue sulfhydryl groups. *Archives of Biochemistry and Biophysics*. 1959; 82: 70-77.
- [16]. Aebi H. [13] Catalase in vitro. *Methods in Enzymology*. 1984; 105: 121-126.
- [17]. Habbu P, Shastry R, Mahadevan K, Joshi H, Das S. Hepatoprotective and antioxidant effects of *Argyrea speciosa* in rats. *African Journal of Traditional, Complementary and Alternative Medicines*. 2008; 5: 158-164.
- [18]. Marklund S, Marklund G. Involvement of the superoxide anion radical in the autoxidation of pyrogallol and a convenient assay for superoxide dismutase. *European Journal of Biochemistry*. 1974; 47: 469-474.
- [19]. Cathcart R, Schwiens E, Ames BN. Detection of picomole levels of hydroperoxides using a fluorescent dichlorofluorescein assay. *Analytical Biochemistry*. 1983; 134: 111-116.
- [20]. Galighor A, Kozloff E. *Essentials of practical microtechnique* 2nd edn. Lea and Febiger, New York. 1976.
- [21]. Brattin WJ, Glende A, Recknagel RO. Pathological mechanisms in carbon tetrachloride hepatotoxicity. *Journal of Free Radicals in Biology & Medicine*. 1985; 1: 27-38.
- [22]. Basu S. Carbon tetrachloride-induced lipid peroxidation: eicosanoid formation and their regulation by antioxidant nutrients. *Toxicology*. 2003; 189: 113-127.
- [23]. Barapatre A, Aadil KR, Tiwary BN, Jha H. In vitro antioxidant and antidiabetic activities of biomodified lignin from *Acacia nilotica* wood. *International Journal of Biological Macromolecules*. 2015; 75: 81-89.
- [24]. Barapatre A, Meena AS, Mekala S, Das A, Jha H. In vitro evaluation of antioxidant and cytotoxic activities of lignin fractions extracted from *Acacia nilotica*. *International Journal of Biological Macromolecules*. 2016; 86: 443-453.

