

Histological and biochemical study on hypoglycemic and antihyperlipidemic effects of aqueous extract of *Cynodon dactylon* in streptozotocin-induced diabetic rats

Madhan KumarSJ^{1*}, S Sundarapandian¹, Christilda Felicia Jebakani¹

*Corresponding author:

Madhan Kumar SJ

¹Department of Anatomy, SRM Medical College Hospital and Research Centre, SRM University, India.

Abstract

Cynodon dactylon has been mentioned in ayurvedic system of Indian medicine to be of value in the treatment of diabetes mellitus. The purpose of this study was to investigate the possible hypoglycemic effects of aqueous extract of the whole plant of *Cynodon dactylon* on blood glucose, plasma insulin, serum lipid profiles and possible histopathological changes in the pancreatic tissue of streptozotocin induced diabetic rats. Type 1 diabetes was induced by streptozotocin (STZ) in rats. One sub-group of rats, received glibenclamide treatment and another received *Cynodon* extract Treatment for 45 days respectively. Blood was analyzed for fasting blood glucose, insulin levels and lipid profiles after treatment. Histopathological sectional studies of the pancreatic islets were done. Treatment of the animals with the aqueous extract from plant at a dose of (500 mg/kg body weight) for 45 days resulted in significant reduction in blood glucose, cholesterol, triglycerides, low-density lipoprotein, and very- low - density lipoprotein in STZ diabetic rats. These biochemical parameters were correlated with the histopathological changes observed in the pancreatic islets of STZ diabetic rats, which structurally proved the effectiveness of the aqueous extract of *C. dactylon* in STZ diabetic rats. The obtained biochemical and histopathological results confirmed the hypoglycemic and antihyperlipidemic effects of aqueous extract of the *C. dactylon* in experimental model of diabetic animals. *Cynodon dactylon* may be useful as a natural supplementary medicine in the treatment of diabetes and its complications.

Keywords: Diabetes mellitus; Streptozotocin; *Cynodon dactylon*; Histopathology; Hypoglycemia; Pancreatic islets.

Introduction

Diabetes mellitus is characterized by multiple metabolic disorder of carbohydrate metabolism resulted in chronic hyperglycemia with insulin deficiency and resistance in the pancreatic β -cells [1]. The prevalence of people with diabetes is projected to rise from 171 million in 2000 to 366 million in 2030. It is estimated that the number of people with diabetes >64 years of age will be >82 million in developing and >48 million in developed countries by 2030 [2]. Natural remedies from medicinal plants are apparently effective with minimum or no side effects; provide an alternative treatment for diabetes.

Herbal drugs or their extract prescribed widely even their biological active compounds are unknown [3]. More than 35,000 plant species are being used worldwide for the medicinal purposes in traditional and ethno medicinal practices [4]. World health organization (WHO) has also recommended the evaluation of traditional medicinal plant for the treatment of diabetes [5]. Several plant species have been identified to possess hypoglycemic

activity, which include *Opuntia streptacantha* Linn, *Trigonella foenum graceum* L, *Momodica charantia* L, *Ficus bengalensis* L, *Gymnema sylvestre* [6].

Phytotherapy continued to be used in several countries, it has been reported that about one- third of medicinal plants used in the treatment of diabetes are considered to be toxic [7]. Although few biochemical studies that scientifically validate the hypoglycemic and antihyperlipidemic effects of aqueous extract of *Cynodon dactylon* has been reported [8, 9]. Histopathological studies that prove the hypoglycemic effect of *Cynodon dactylon* in the pancreatic islet architecture have not been reported elsewhere in the literature. Streptozotocin (STZ) is frequently used to induce diabetes in experimental animals through its toxic effects on pancreatic β -cells [10, 11, 12, 13].

Reports have shown that hyperglycemia is accompanied by hyperlipidemia in STZ- induced diabetes mellitus [14, 15]. The present study is aimed at evaluating the possible hypoglycemic and antihyperlipidemic effects of aqueous extract of *C. dactylon* on fasting blood glucose and insulin and lipid profiles in normal and STZ- induced diabetic rats, along with the histopathological changes observed in the pancreatic islet cellular architecture.



Materials and methods

Experimental animals

Adult male albino wistar rat (*Rattus norvegicus*) weighing approximately 150-200g (housed 3 per cage) were acclimatized and housed in the central animal house of our institute. All animals were kept in 12:12 hr light: dark cycle, at a room temperature of $22\pm 2^\circ\text{C}$. Rats were fed with standard rat pellet supplied by Provimi animal nutrition India Ltd, Bangalore, India, were also allowed free access to water. Animal experimentation was carried out under the supervision of on duty veterinary medical officer in accordance to the ethical norms approved by the Institutional animal ethical committee. (Ref: 45/IAEC/2011)

Chemicals and reagents

Reagents were obtained from Thermo Fischer scientific India and Merck (India) and were of the highest commercial grade available.

Preparation of the aqueous extract

Cynodon dactylon was collected from kanniyakumari district of Tamilnadu, south India and authenticated by Dr Manian, Director of plant sciences, Bharathiar University, Coimbatore, Tamilnadu, south India. The whole plant of *Cynodon dactylon* was washed with tap water, air dried, and grinded in a mechanical blender. The dried powder (100 g) of *Cynodon dactylon* was extracted with distilled water in a soxhlet extractor and the resultant extract was concentrated in a rotary vacuum evaporator, the concentrated dark extract stored in air tight container. The resultant yield of this extract was 6.6%.

Induction of experimental diabetes

Animals were fasted overnight and diabetes was induced by single intraperitoneal injection of streptozotocin (Sisco research laboratories, Mumbai, India) at a dose of 45mg/kg body weight, prepared in 0.1 M Citrate buffer at pH 4.5 [16]. To overcome drug induced hypoglycemia, animals were allowed to drink 5% glucose solution overnight. Citrate buffer alone injected to control rats. After 72 hours of STZ injection, fasting blood glucose levels of each animal were analyzed. Animals with fasting blood glucose levels > 200 mg/dl were considered as diabetic and taken for the study.

Experimental design

The rats were randomly divided into the following five groups with six rats in each group:

- Group I: normal control rats received only vehicle solutions.
- Group II: diabetic control rats served as positive control group received single dose of STZ (45 mg/kg, intraperitoneally).
- Group III: diabetic rats received glibenclamide (5mg/kg, per oral).
- Group IV: normal control rats received the aqueous extract of *Cynodon dactylon* (500 mg/kg, per oral).
- Group V: diabetic rats received the aqueous extract of *Cynodon dactylon* (500 mg/kg, per oral).

Animals were treated by oral gavage once a day, preferably in the morning for a period of 45 days. At the end of the experimental period, the animals were fasted overnight; blood was collected by Retro-orbital puncture and then sacrificed under ether anesthesia.

Collection of tissue samples for histopathology

The pancreas were dissected out, fixed in 10% neutral buffered formalin solution and embedded in paraffin wax for routine histological procedure. Sections of 5-6 μm thickness were cut on a Leica rotary microtome and stained with hematoxylin and eosin (H&E) for general histological study [17]. Sections were also stained with Masson's trichrome stain to examine the collagen fibers [18]. The stained slides were then photomicrographed with APCAM -5 USB 2 digital cameras attached to a computer monitor, supplied by ADELTA VISION OPTEC India microscope Ltd.

Estimation of blood glucose

Blood glucose was analyzed by O-toluidine method [19]. A 0.1 ml of the blood was mixed with 1.9ml of 10% trichloroacetic acid solution to precipitate and then centrifuged. A 1ml of supernatant was mixed with 4ml of O-toluidine reagent and was kept in boiling water bath for 15 min and then cooled. The absorbance was read at 620 nm. Data were expressed as mg/dl.

Plasma insulin

Plasma insulin was determined by the method of Andersen et al, 1993 [20], using assay kit (Boehringer Mannheim kit).

Estimation of lipid profile

Total cholesterol (TC), high-density lipoprotein (HDL) cholesterol and Triglyceride (TG) levels in serum were determined by the method of Yadav et al. 2008 [21], using commercially available kits. Very low-density lipoprotein (VLDL) and low-density lipoprotein (LDL) were estimated by Friedwald et.al.'s (1972) formula which states: VLDL cholesterol = TG/5 and LDL cholesterol = TC - (VLDL + HDL cholesterol).

Statistical analysis

Results are expressed as mean \pm standard error of the mean. Comparison of the means between groups was performed by one-way analysis of variance (ANOVA) followed by post hoc of Dunnett's test, which was used to compare means between positive control (group II) rats versus all other groups. Statistical analyses were done using Graphpad Instat trial version 3.0a (Graphpad software, San Diego, California, USA). All statistical tests were two-tailed and a p value of 0.05 or less was considered statistically significant.



Table 1 Effects of aqueous extract of *Cynodon dactylon* on blood glucose and plasma insulin levels in STZ- induced diabetic rats.

Groups	Blood glucose (mg/dl)	Plasma Insulin (μ U/ml)
I	95.5 \pm 2.12 ^a	16.71 \pm 0.26 ^a
II	371.83 \pm 11.55	6.6 \pm 0.15
III	120.5 \pm 2.95 ^b	13.4 \pm 0.17 ^a
IV	87.16 \pm 0.70 ^b	16.56 \pm 0.31 ^a
V	117.5 \pm 2.39 ^a	13.46 \pm 0.14 ^a

Values are given as mean \pm SEM for 5 groups of 6 rats in each group.

^a $p < 0.01$ indicates significance versus diabetic control (Group II) by one – way ANOVA followed by post hoc Dunnett's test.

^b $p < 0.05$ indicates significance versus diabetic control (Group II) by one – way ANOVA followed by post hoc Dunnett's test.

Effects of aqueous extract of *C.dactylon* on blood glucose and plasma insulin

Table 1 shows the level of blood glucose and plasma insulin in control and experimental diabetic rats. There was a significant elevation in blood glucose level ($p < 0.01$, one-way ANOVA) with significant reduction in plasma insulin levels ($p < 0.01$, one-way ANOVA,

post hoc Dunnett's test) in STZ diabetic rats (group II), compared with control rats (group I) and with diabetic rats treated with *C.dactylon* at a dose of 500 mg/kg, body weight. Administration of aqueous extract of *C.dactylon* at a dose of 500 mg/kg, body weight to normal rats (group IV) maintained the normal levels of blood glucose and plasma insulin which was similar to control rats (group I) and showed significant ($p < 0.05$ post hoc Dunnett's test) when compared to STZ- induced diabetic rats (group II). The glibenclamide treated diabetic rats showed significant reduction in the levels of blood glucose ($p < 0.05$, Post hoc Dunnett's test) and increased plasma insulin gain to near normal level ($p < 0.05$, post hoc Dunnett's test) when compared with STZ-induced diabetic rats (group II).

Table 2 Effect of aqueous extract of *Cynodon dactylon* on serum lipid profile levels in STZ – induced diabetic rats.

Groups	I	II	III	IV	V
TC (mmol/L)	2.07 \pm 0.01 ^a	4.85 \pm 0.03	2.48 \pm 0.02 ^a	2.13 \pm 0.01 ^a	2.37 \pm 0.03 ^a
TG(mmol/L)	0.45 \pm 0.01 ^a	1.65 \pm 0.01	0.75 \pm 0.01 ^a	0.45 \pm 0.01 ^a	0.63 \pm 0.02 ^a
VLDL(mmol/L)	0.20 \pm 0.01 ^a	0.75 \pm 0.01	0.34 \pm 0.01 ^a	0.20 \pm 0.01 ^a	0.28 \pm 0.01 ^a
LDL (mmol/l)	0.39 \pm 0.01 ^a	3.32 \pm 0.02	0.82 \pm 0.02 ^a	0.46 \pm 0.01 ^a	0.73 \pm 0.02 ^a
HDL (mmol/L)	1.45 \pm 0.02 ^a	0.75 \pm 0.01	1.30 \pm 0.02 ^a	1.46 \pm 0.02 ^a	1.35 \pm 0.02 ^a

TC: total cholesterol; TG: triglyceride; VLDL: very – low – density lipoprotein; LDL: low- density lipoprotein; HDL: high – density – lipoprotein.

Values are given as mean \pm SEM for 5 groups of 6 rats in each group.

^a $p < 0.01$ indicates significance versus diabetic control (group II) by one –way ANOVA followed by post hoc Dunnett's test.

Effect of aqueous extract of *C.dactylon* on the levels of serum lipid profiles

Table 2 shows the levels of Serum TC, TG, LDL, VLDL and HDL levels in the control and experimental diabetic rats. Serum TC, TG, LDL and VLDL were significantly higher ($p < 0.01$, post hoc Dunnett's test) in STZ diabetic rats (group II) than those in normal control rats (group I). Decreased levels of HDL were observed in STZ- induced diabetic rats when compared to normal control rats (group I) ($p < 0.01$, post hoc Dunnett's test). Treatment with aqueous extract of *C. dactylon* and glibenclamide resulted in a significant decrease in TC, TG, LDL and VLDL levels, when compared to those in STZ- induced diabetic rats ($p < 0.01$, post hoc Dunnett's test). Serum HDL levels were significantly ($p < 0.01$, post hoc Dunnett's test) increased in the treated diabetic rats (group V and III). Normal rats treated with aqueous extract of *C.dactylon* maintained the normal levels of TC, TG, LDL, HDL and VLDL ($p < 0.01$, post hoc Dunnett's test) when compared with STZ-induced diabetic rats.

Histological observation of the pancreas stained with hematoxylin and eosin

The control rats (group I) showed the normal lobular pattern of the pancreas, with clear distinct islets of langerhans, interspersed among the pancreatic acini, as round to oval shape, compact masses of β - cells at the center arranged in cords separated by a network of blood capillary, and alpha cells at the periphery (Figure 1). In STZ diabetic control (group II) the compactness of islets was lost, due to loss of cellular population indicating the degeneration and necrosis of islet cells (Figure 2). In diabetic rats treated with glibenclamide (5 mg/kg, bodyweight) (group III) cellular density of pancreatic islets increased with vacuolization of β - cell were seen, but complete regeneration of pancreatic islets not seen (Figure 3). In normal rats treated with aqueous extract of *C. dactylon* (500 mg/kg, bodyweight) (group IV) the histological pattern of pancreatic islet architecture were similar to control rats (group I) showing the non-toxic nature of the plant extract (Figure 4). Diabetic rats treated with aqueous extract of *C. dactylon* (500 mg/kg, bodyweight) (group V) showed marked rejuvenation of the pancreatic islets with an increase in size and cellular density, as comparable to control rats (group I). However, degeneration of few β - cells with vacuolated cytoplasm are still seen (Figure 5).



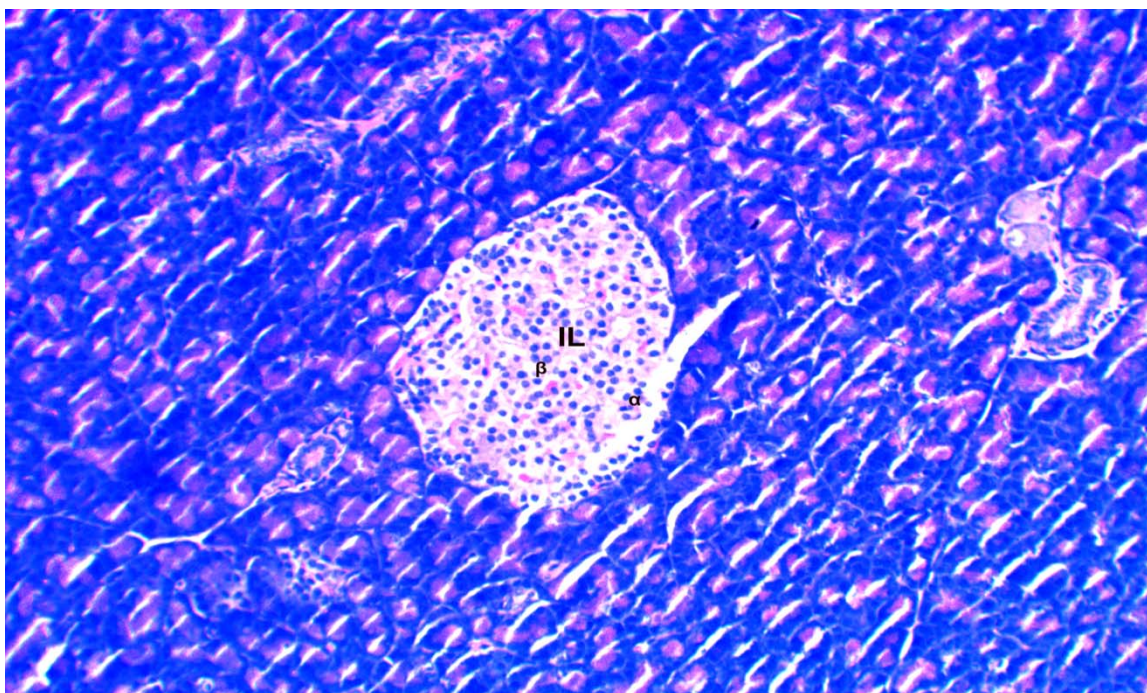


Figure 1 Section of pancreas of control rats (group I) showing normal islets architecture. H&E magnification X 100.
Legends IL: islets of langerhans β:beta cells α: alpha cells

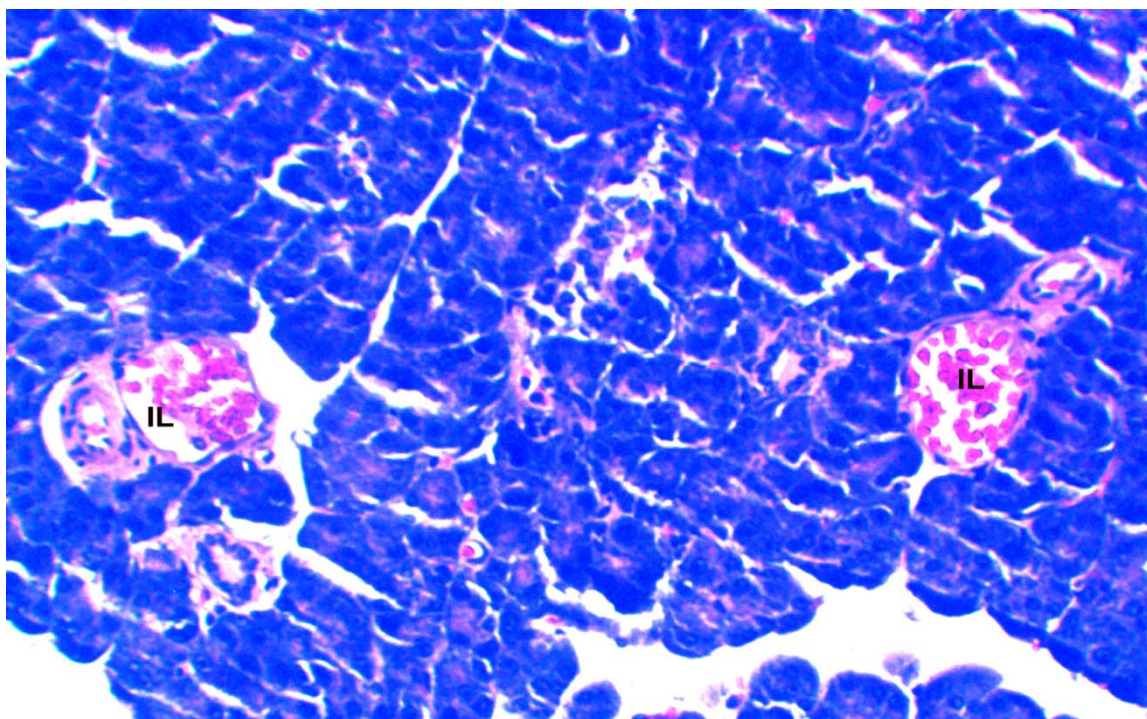


Figure 2 Section of pancreas of diabetic control rats showing destruction of islet architecture and shrinkage of islet mass. H&E magnification X 100
Legends
IL: islets of langerhans



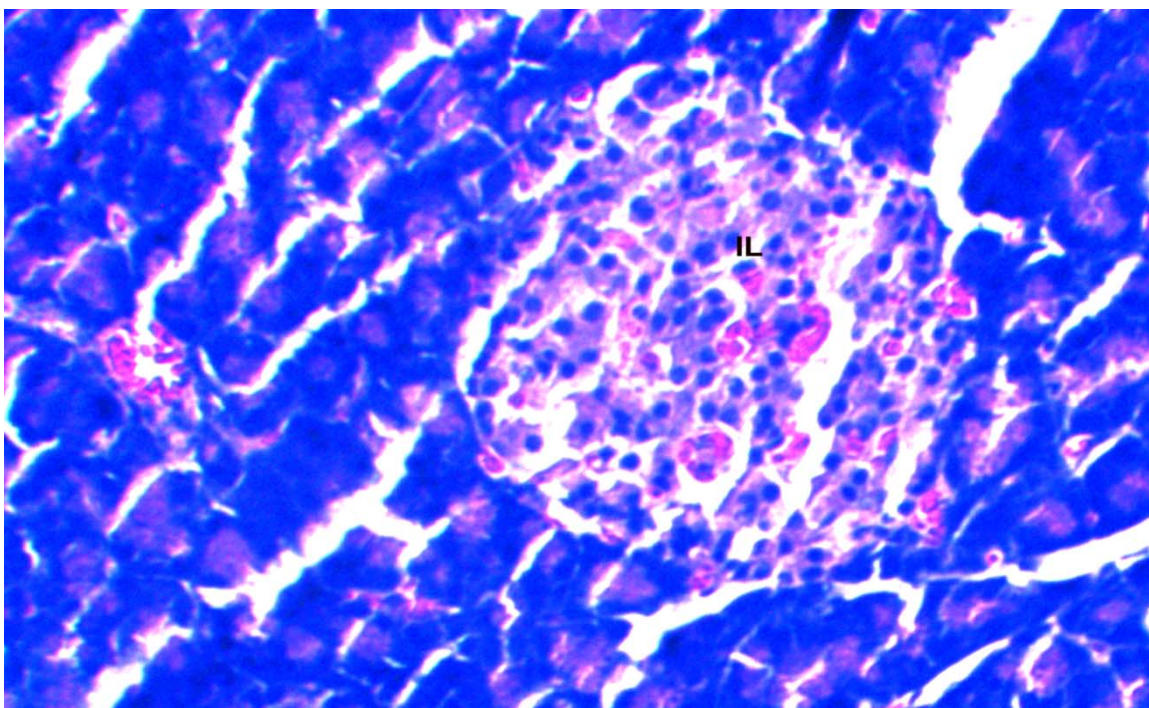


Figure 3 Section of pancreas of diabetic rats treated with glibenclamide (group III) showing regeneration of islet architecture. H& E magnification X100

Legends

IL: islets of langerhans

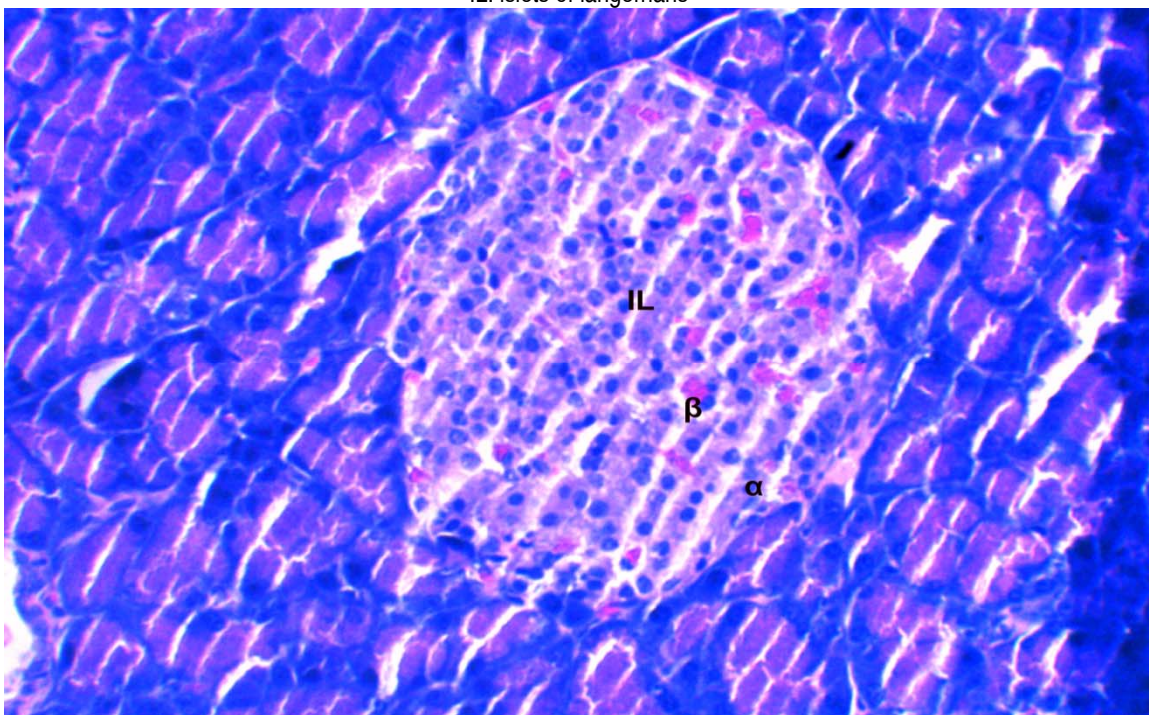


Figure 4 Section of pancreas of normal rats treated with aqueous extract of *C.dactylon* (group IV) showing normal clear islet architecture. H&E magnification X100

Legends

IL: islets of langerhans β: beta cells : alpha cells



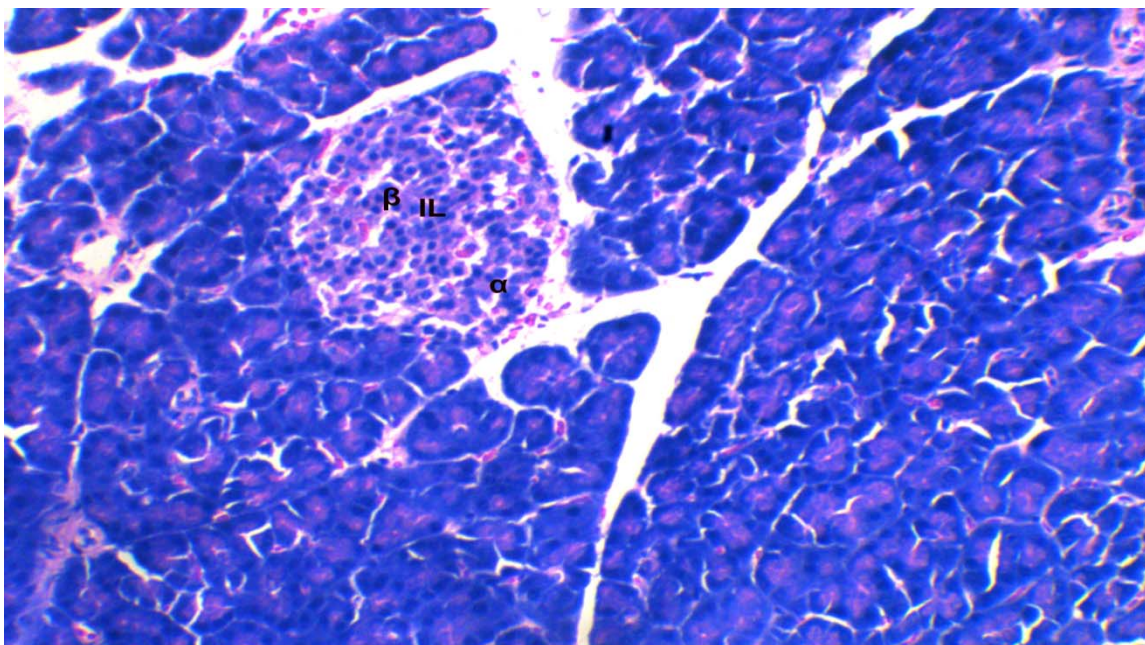


Figure 5 Section of pancreas of diabetic rats treated with aqueous extract of *C.dactylon* (Group v) showing rejuvenation of islet architecture. H&E magnification X100

Legends

IL: islets of langerhans β: beta cells α: alpha cells

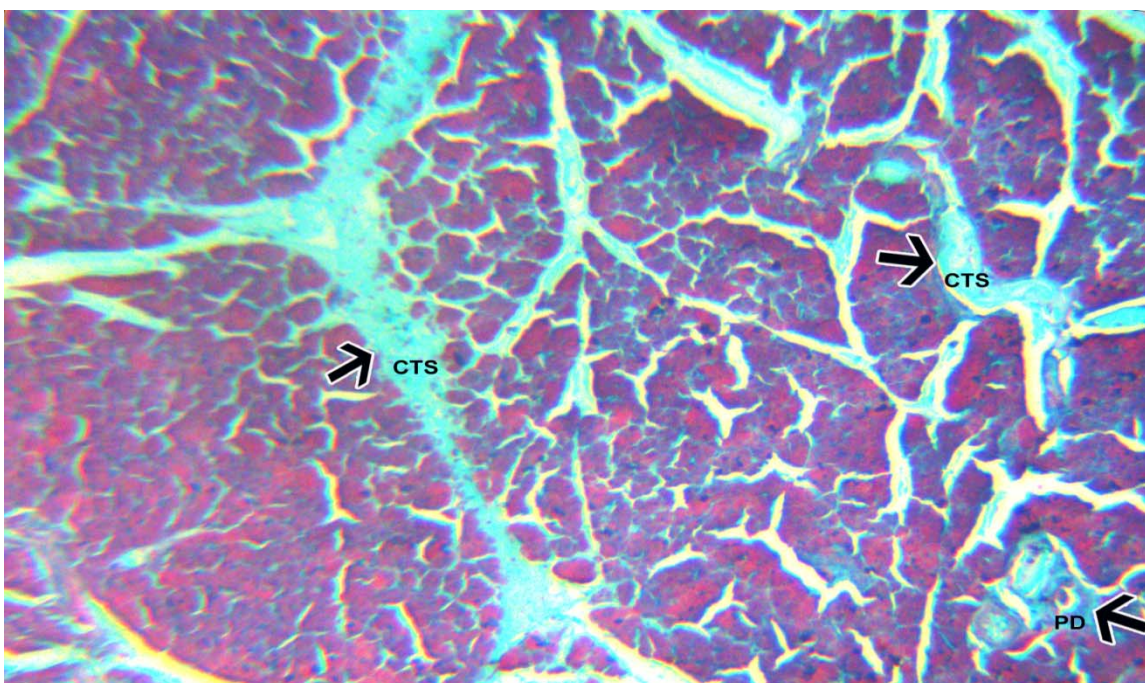


Figure 6 Section of pancreas of normal control rats (group I) stained with Masson's trichrome showing thin bundles of collagen fibers (black arrows) around islets and pancreatic interlobular connective septa. Magnification x100.

Legends

CTS: connective tissue septa PD: pancreatic ductule



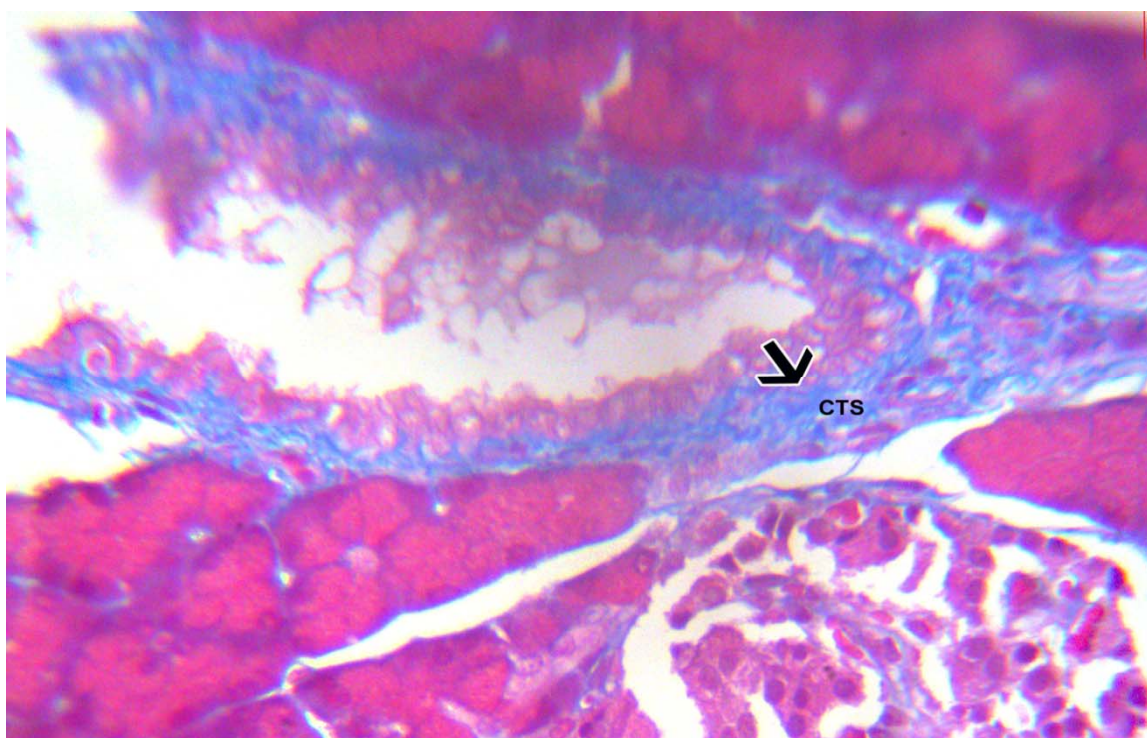


Figure 7 Section of pancreas of diabetic control rats (group II) stained with Masson's trichrome showing thick bundles of collagen fibers (black arrow) around pancreatic ductule. Magnification X100

Legends

CTS: connective tissue septa

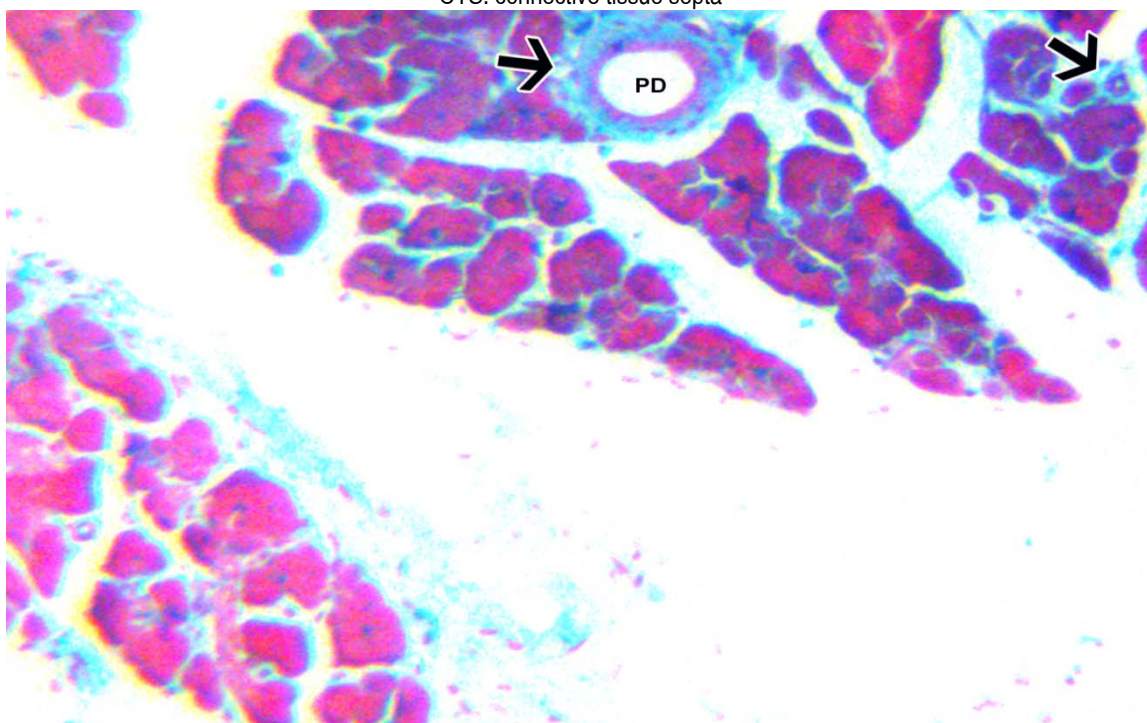


Figure 8 Section of pancreas of diabetic rats treated with glibenclamide (group III) stained with Masson's trichrome showing moderate bundles of collagen fibers (black arrow) around pancreatic ductule (PD). Magnification X100



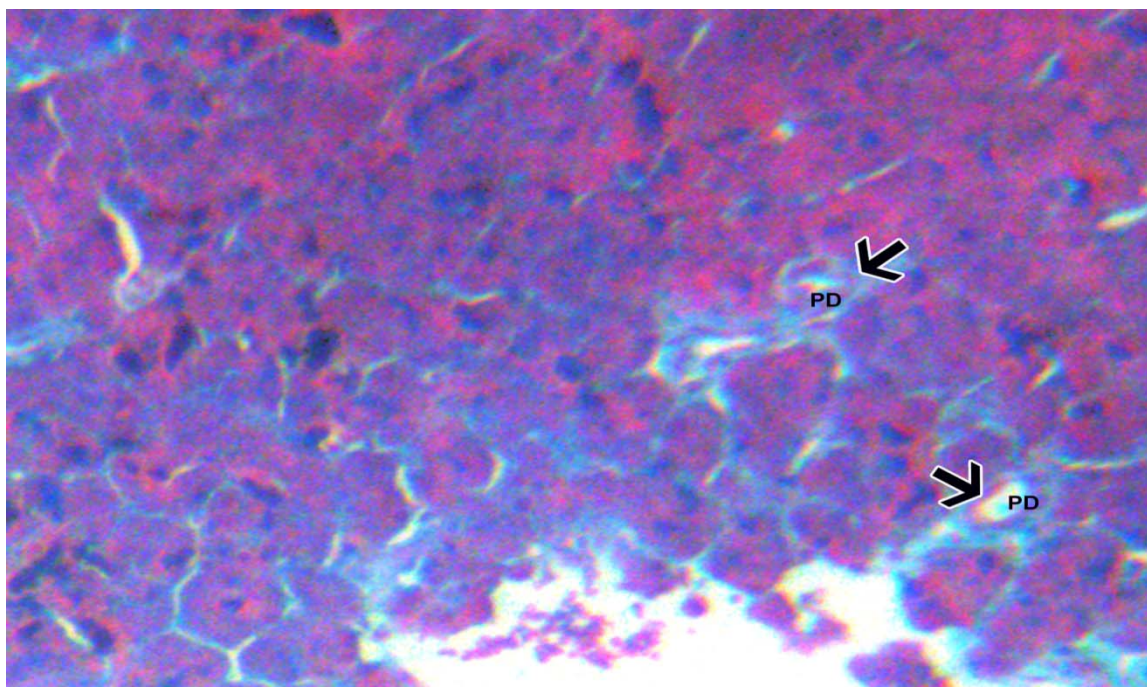


Figure 9 Section of pancreas of normal rats treated with aqueous extract of *C.dactylon* (group IV) stained with Masson's trichrome showing thin bundles of collagen fibers (black arrows) around pancreatic ductule(PD). Magnification X100

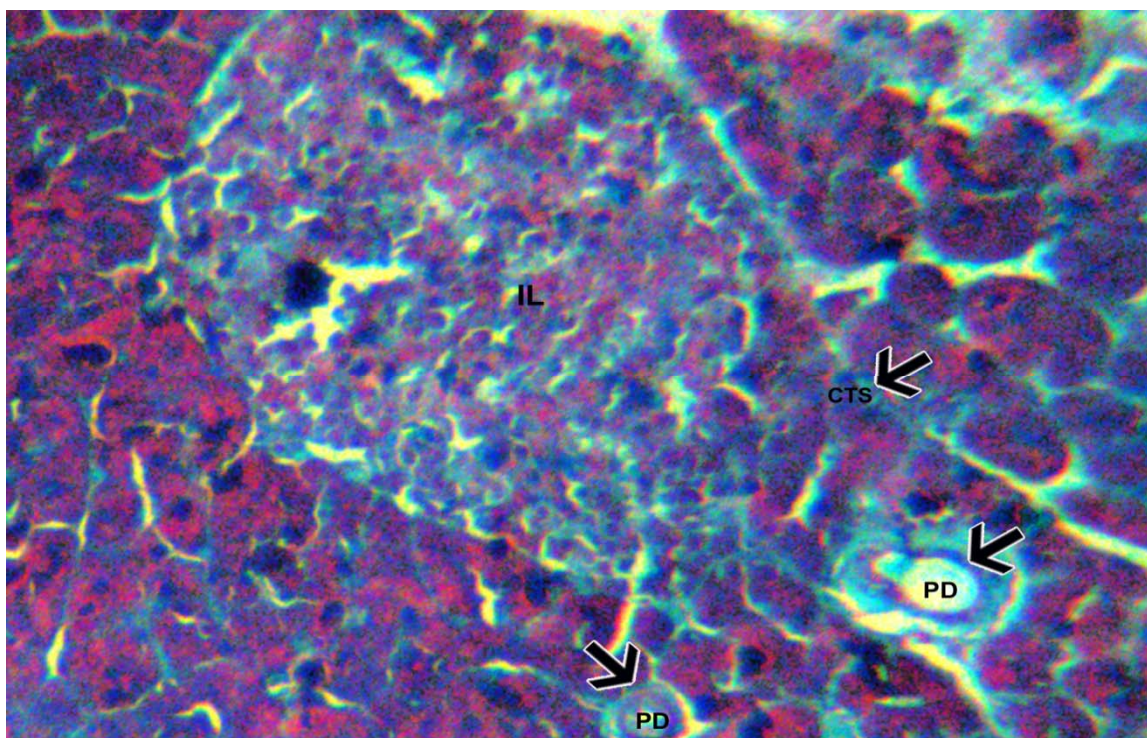


Figure 10 Section of pancreas of diabetic rats treated with aqueous extract of *C.dactylon* (group V) stained with Masson's trichrome showing thin bundles of collagen fibers (black arrows) around pancreatic ductule (PD). Magnification X100
Legend CTS: connective tissue septa PD: pancreatic ductule IL: islets of langerhans



Histological observation of the pancreas stained with Masson's trichrome stain

In the control rats (group I) thin evenly arranged sheet of collagen fibers were seen between the pancreatic acini and the islets of langerhans and also around the pancreatic ductules (Figure 6). Marked thickening of collagen bundles around pancreatic ductules were seen in diabetic control rats (group II) (Figure 7). In diabetic rats treated with glibenclamide (5 mg/kg, bodyweight) (group III) and with aqueous extract of *C.dactylon* (500 mg/kg, bodyweight) (group V) exhibited the normal pattern of collagen bundles around pancreatic ductules which were similar to control rats (group I) showing the effectiveness of the treatment (Figure 8, 10). Normal rats treated with aqueous extract of *C.dactylon* (500 mg/kg, bodyweight) (group IV) showed no significant histopathological changes in the arrangement of collagen bundles around the islets and pancreatic ductules, which were similar to control rats (group I) (Figure 9).

Discussion

Diabetes mellitus associated with progressive metabolic derangement, worsening glycemic control and morphological changes in the pancreas, liver and other organs [22, 23]. Oxidative stress is known to play a significant role in the induction of these processes [24]. Pancreatic insulin reserve is an important parameter of islet function with tight coupling between insulin secretion and production being necessary for adequate functioning of pancreatic β - cells [25]. It has been shown that insulin deficiency in diabetes mellitus lead to accumulation of lipids especially TG and TC in diabetic patients [26]. High concentration of cholesterol in human serum is one of the primary factors in the development of atherosclerosis [27]. Marked hyperlipidemia in diabetic state may be regarded as a consequence of the uninhibited actions of lipolytic hormones on the fat depot [28]. Further in diabetic state, there is inactivation of lipoprotein lipase by which free fatty acids are converted into phospholipids and cholesterol, which are finally discharged into blood, causing an elevation of serum phospholipids levels [29].

In our study, 45 days of treatment with aqueous extract of *C.dactylon* at a dose of (500 mg/kg, body weight) had significantly reduced the fasting blood glucose levels and increased plasma insulin in STZ –induced diabetic rats. Blood glucose lowering potential of aqueous extract of *C.dactylon* might be due to activation of β - cells giving insulinogenic effect through the stimulation of regeneration process and reactivation of β - cells, also the presence of flavonoids in the extract may be responsible for the stimulation of glucose uptake in peripheral tissues and regulation of activity and/or expression of the rate limiting enzymes involved in carbohydrate metabolism [30]. In the present study, treatment with aqueous extract of *C.dactylon* at a dose of 500 mg/kg, bodyweight, markedly decreased both serum TC, TG and LDL levels by 57%, 61%, and 75%, as high levels of LDL cholesterol

predispose to atherosclerotic state [31]. HDL levels were also significantly increased by more than 80% in *C.dactylon* aqueous extract treated rats. These results were similar to those reported by many authors on medicinal plants, which exhibited antihyperlipidemic activity [32, 33, 8].

The biochemical findings of our study were correlated with the histopathological changes in the pancreatic islets of normal and experimental animals, which reveal that treatment of diabetic rats with 500 mg/kg, bodyweight of aqueous extract of *C.dactylon* showed substantial recovery of pancreatic islet architecture, which also showed improvement in size, number and cellular density of the islets. The observed histopathological findings were similar to the findings, reported by very few authors [34, 35, 36]. Histological examination of Masson's trichrome stained sections of STZ-induced diabetic rats showed increased collagen deposition mainly around pancreatic ductules, whereas collagen bundles were fairly similar to control rats in pancreatic sections of the *C.dactylon* treated STZ- induced diabetic rats. This increased collagen could be attributed to the chronic accompanying auto-immune reactions, as insulin dependent diabetes mellitus is characterized by the activation of autoimmunity towards β -cells [35].

In summary, our study clearly demonstrate that aqueous extract of *C.dactylon* has been shown histopathologically and biochemically to possess hypoglycemic and antihyperlipidemic activity, which act by improving the insulin secretion due to activation of β -cells. However the exact mechanism to prove such effects still remains unclear. More studies on histochemistry and immunohistochemistry are underway to further prove the histopathological changes in the pancreatic islet of STZ-induced diabetic rats treated with aqueous extract of *C.dactylon*.

Conclusion

In diabetic rats the aqueous extract of *C.dactylon* at a dose of 500 mg/kg, bodyweight exhibited significant hypoglycemic and antihyperlipidemic effect, shown biochemically and histologically. The aqueous extract of *C.dactylon* exhibits ameliorative effects almost similar to the standard group (glibenclamide 5 mg/kg, bodyweight). Histopathological observations made in this study also warrant that aqueous extract of *C.dactylon* is effective in reducing the islet cellular toxicity induced by Streptozotocin (STZ). Thus our study clearly indicates that aqueous extract of *C.dactylon* might be of therapeutic value in the treatment of diabetes and its associated complications.

Author's contribution

MKSJ identified the research concept and carried out the practical work

CFJ supervised, reviewed the entire study.

Conflict of interest

The authors declared no conflict of interest.



Funding

This research received no specific grant from any funding agency in the public, commercial, or not-for-profit sectors.

Acknowledgements

We extend our sincere thanks to Dr.Thangaraju, pro-vice-chancellor, SRM University, Dr. James pandian, Dean, SRM Medical college, Dr. D. Balakrishnan, Dean, Medical Research, SRM University, Dr.sundarapandian,Department head (Anatomy) for their valuable support and to Dr. D. Alvin, Veterinary medical officer, department of animal house, SRM Medical College, for helping in animal experimentation techniques/procedures.

References

- [1]. American Diabetes Association. Diagnosis and classification of diabetes mellitus. *Diabetes Care*. 2010, 33: S62-S69.
- [2]. Wild S, Roglic G, Green A, Sicree R and King H. Global prevalence of diabetes estimates for the year 2000 and projections for 2030. *Diabetes Care*. 2004, 27: 1047-1053.
- [3]. Gupta RK, Kesari AN, Murthy PS, Chandra R, Tandon V and Watal G. Hypoglycemic and antidiabetic effect of ethanolic extract of leaves of *Annona squamosa* L. in experimental animals. *Journal of Ethnopharmacology*. 2005, 99 (1): 75-81.
- [4]. Kumar A, Sawarkar HA and Deshnuhk VS, et al. *Cynodon dactylon* (L.) pers.: Pharmacological actions and medicinal applications. *International Journal of Herbal Drug Research*. 2011, 1: 1-7.
- [5]. WHO, Expert committee on diabetes mellitus-technical report series 646. 2nd report. Geneva, *World Health Organization*. 1980: 1-80.
- [6]. Mohammed B, Ziyat A, Mekhfi H, Tahri A and Legssyer A. Medicinal plants with potential antidiabetic activity- a review of ten years of herbal medicine research (1990-2000). *International Journal of Diabetes and Metabolism*. 2006, 14: 1-25.
- [7]. Marles RJ and Farnsworth NR. Plants as sources of antidiabetic agents. *Economic and Medicinal Plant Research*. 1994, 6: 149-187.
- [8]. Singh SK Kesari AN, Gupta RK, Jaiswal D and Watal G. Assessment of antidiabetic potential of *Cynodon dactylon* extract in streptozotocin diabetic rats. *Journal of Ethnopharmacology*. 2007, 114: 174-179.
- [9]. Mahesh N and Brahatheeswaran D. Antihyperglycemic activities of aqueous and ethanolic extracts *Cynodon dactylon* (Linn). Streptozotocin induced diabetic rats. *Asian Journal of Biochemistry*. 2007, 2(1): 66-72.
- [10]. Kalendra B Oztruk M and Tuncdemir M, et al. Renoprotective effect of valsartan and enalapril in STZ – induced diabetes in rats. *Acta Histochemica*. 2002, 104: 123-130.
- [11]. Kim MJ, Ryu GR and Chung JS, et al. Protective effect of epicatechin against the toxic effects of STZ on rat pancreatic islets: in vivo and in vitro. *Pancreas*. 2003, 26: 292-299.
- [12]. Stefek M, Tribulova N, Gajdoski A and Gajdosikova A . The pyridoindole antioxidant stobadine attenuates histochemical changes in kidney of STZ- induced diabetic rats. *Acta Histochemica*. 2002, 104: 413-417.
- [13]. Yamagishi N, Nakayama K, Wakatsuki T and Hatayama T. Characteristic changes of stress protein expression in streptozotocin induced diabetic rats. *Life Sciences*. 2001, 9: 2603-2609.
- [14]. Sharma SR, Dwivedi SK and Swarup D. Hypoglycemic and hypolipidemic effects of *Cinnamomum tamale* nees leaves. *Indian journal of Experimental Biology*. 1996, 34: 372-374.
- [15]. Rao BK, Kesavulu MM, Giri R and Rao CA. Antidiabetic and hypolipidemic effects of *Momordica cymbalaria* Hook. Fruit powder in alloxan-diabetic rats. *Journal of Ethnopharmacology*. 1999, 67: 103-109.
- [16]. Siddique O, Sun Y, Lin JC and Chien YW. Facilité de transport transdermique de l' insuline. *Journal of Pharmaceutical sciences*. 1987, 76: 341-345
- [17]. Bancroft JD and Gamble MN. Theory and practice of histological techniques. 5th ed. Edinburgh, London: Churchill-Livingstone. 2002:175.
- [18]. Bancroft J and Stevens A. Theory and practice of histological techniques. 2nd ed. New York, NY: Churchill-Livingstone. 1982: 131-135.
- [19]. Sasaki T, Matsy S and Sonae A. Effect of acetic acid concentration on the colour reaction in the O-toluidine boric acid method for blood glucose estimation. *Rinsho kagaku*. 1972, 1: 346-353.
- [20]. Andersen L, Dinesen B, Jorgensen PN, Poulsen F and Roder MF. Enzyme immunoassay for intact human insulin in serum or plasma. *Clinical Chemistry*. 1993, 38: 578-582.
- [21]. Yadav JP, Saini S, Kalia AN and Dangi AS. Hypoglycemic and hypolipidemic activity of ethanolic extract of *Salvodara oleoides* in normal and alloxan-induced diabetic rats. *Indian Journal of Pharmacology*. 2008, 1: 23-27.



- [22]. Cook MN, Girman CJ, Stein PP, Alexander CM and Holman RR. Glycemic control continues to deteriorate after sulfonylureas are added to metformin among patients with type 2 diabetes. *Diabetes Care*. 2005, 28: 995-1000.
- [23]. Cristina L, Roberto L and Stefano DP. β -cell failure in type 2 diabetes mellitus *Current Diabetes Reports*. 2008, 8: 179-184.
- [24]. Baynes JW and Thorpe SR. The role of oxidative stress in diabetic complications *Current Opinion in Endocrinology Diabetes and Metabolism*. 1999, 3: 277-284.
- [25]. Kaiser N, Leibowitz G and Neshier R. Glucotoxicity and β - cell failure in type 2 diabetes mellitus *Journal of Pediatric Endocrinology and Metabolism*. 2003, 16: 5-22.
- [26]. Ashokkumar BS, Lakshman K, Jayaveera KN, Shekar DS, Khan S and Thippeswamy BS, et al. Antidiabetic antihyperlipidemic and antioxidant activities of methanolic extract of *Amaranthus viridis* Linn. in alloxan induced diabetic rats. *Experimental and Toxicologic Pathology*. 2012, 64: 75-79.
- [27]. Milago FI and Martinez JA. Effects of oral administration of β_3 - adrenergic agonist on lipid metabolism in alloxan induced diabetic rats. *Journal of Pharmacy and Pharmacology*. 2000, 52: 851-856.
- [28]. Goodman LS and Gilman A. The pharmacological basis of therapeutics. 7th ed. New York NY: Macmillan 1985, 1490-1510.
- [29]. Pushparaj PN, Low HK, Manikandan BKH, Tan and Tan CH. Antidiabetic effects of *Cichorium intybus* in streptozotocin- induced diabetic rats. *Journal of Ethnopharmacology*. 2007, 111: 430-434.
- [30]. Gupta R, Mathur M, Bajaj VK, Katariya P, Yadav S and Kamal R, et al. Evaluation of antidiabetic and antioxidant activity of *Moringa oleifera* in experimental diabetes. *Journal of Diabetes*. 2012, 4: 164-171.
- [31]. Temme EH, Van Hoydonck PG, Schouten EG and Kesteloot H. Effects of a plant sterol enriched spread on serum lipids and lipoproteins in mildly hypercholesterolemic subjects. *Acta Cardiologica*. 2002, 57: 111-115.
- [32]. Mhetre NK, Bandawana DD and Patel AN. Antihyperglycemic activity of hydroalcoholic extract of *Cassia auriculata* Linn. (Caesalpinaceae) aerial parts in streptozotocin induced diabetic rats. *Pharmacologia*. 2014, 155-171.
- [33]. Kasetti RB, Rajasekhar MD and Kondetti VK, et al. Antihyperglycemic and antihyperlipidemic activities of methanol:water (4:1) fraction isolated from aqueous extract of *Syzygium alternifolium* seed in streptozotocin induced diabetic rats. *Food and Chemical Toxicology*. 2010, 48: 1078-1084.
- [34]. Rao S, Rao S and Shettar M. Histopathological and biochemical studies on the effect of *Trigonella foenum graecum* and *Coccinia indica* extracts in streptozotocin induced diabetic rats. *International Journal of Pharma and Biosciences*. 2014, July; 5(3): (B) 136-144.
- [35]. Yassa HD, Tohamy AF. Extract of *Moringa oleifera* leaves ameliorates streptozotocin –induced diabetes mellitus in adult rats. *Acta Histochemica*. 2014, 116: 844-854.
- [36]. Gopal V, Mandal V and Mandal SC. Biochemical investigation of standardized *Wattakaka volullis* leaf petroleum ether cold macerated extract against experimentally induced diabetes in the rat. *Pharmacologia*. 2013, 391-399.

