

Effects of FructusChaenomelis on longitudinal bone growth in adolescent rats

Chung Hun Lee¹, Do Yeon Lee², JiHoon Jeong², Tae Jin Lee¹, Eon Sub Park¹

*Corresponding author:

Chung Hun Lee

¹Department of Pathology, College of Medicine, Chung-Ang University, Seoul 156-756, Republic of Korea

²Department of Pharmacology, College of Medicine, Chung-Ang University, Seoul 156-756, Republic of Korea

Abstract

This study was designed to investigate whether Fructuschaenomelis (FC) fruit extract, distilled with ethanol, promotes longitudinal bone growth. Male Sprague-Dawley rats were divided into three groups: control, recombinant human growth hormone (rhGH), and FC treatment. During the 10 days, the control group was administered with normal saline, the rhGH group received subcutaneous injection of rhGH (20 μ g/kg), and the FC group was treated with FC extract by oral gavage, daily. To evaluate the longitudinal bone growth of rats, micro-computed tomography analysis, radiographic measurement, histologic examination, 5-bromo-2'-deoxyuridine (BrdU) immunohistochemistry, and serum osteocalcin level were performed. All of the evaluated parameters using micro-CT (bone volume fraction, bone surface/volume ratio, the thickness and number of trabeculae, and trabecular separation) revealed no significant difference among the groups. The total tibia length, measured by radiographic analysis, was slightly increased in rhGH group and FC group in comparison with the control group. Also the thickness of growth plate (proliferative zone/ hypertrophic zone), BrdU-labeling indices (the number of BrdU-positive chondrocytes/total number of chondrocytes), and serum osteocalcin levels showed significant increase in rhGH group and FC group comparison with the control group. Thus, the results demonstrate that FC fruit extract judged to be a promoting potential for longitudinal bone growth in adolescent rats.

Keywords: : Fructuschaenomelis extract, bone growth, rat

Introduction

Growth hormone (GH) treatment is one of the methods to increase the final height[1]. GH stimulates bone growth by directly acting on GH receptor of osteoblasts and generating of insulin-like growth factor-1, indirectly. Since 1985, when the use of recombinant human GH (rhGH) was approved, GH has been utilized in various conditions, such as idiopathic short stature, Prader-Willi syndrome, and chronic renal failure[2]. Nevertheless, adverse effects of rhGH therapy are reported as follows: prepubertal gynecomastia, benign intracranial hypertension, insulin resistance, and so on[3]. In addition, development of neoplasm is a matter of concern because GH possesses mitogenic and antiapoptotic properties[3]. High cost is another drawback of rhGH treatment (about \$25,000 per year for a child weighing 36 kg)[4]. Thus, it is required to develop an alternative to rhGH.

The fruits of Chaenomeles sinensis are used in traditional medicine of Korea, Japan, and China. According to Dongeuibogam, an encyclopedic bible of Korean traditional medicine, they are effective on strengthening bones and muscles. Their pharmacologic activities, such as antidiabetic activity[5] and antipruritic effect[6], have been experimentally studied. However, to our knowledge, there is no published report about the effect of Fructuschaenomelis(FC), the pharmaceutical name of Chaenomeles fruit, on bone growth. In this study, we report its influence on the longitudinal bone growth.

Materials and methods

Animals

Male Sprague-Dawley rats (Hamamatsu, Japan) of 3 weeks old, weighing 80-90g, were used in this experiment. They were housed for 3-4 days of adaptation in a temperature-controlled room on a 12-h light/dark cycle and given food and water libitum. This project was performed according to the guidelines of the Institutional Animal Care and Use Committee of the Institute for Molecules-Based New Drug Development.

Chemicals

For extraction, FC was purchased from Woori Oriental Medicine Materials Co. (Seoul, Korea). Polysaccharides were extracted by a technique with hot water decoction[7, 8]. The acquired polysaccharides extracts were freeze-dried.

Drug treatment

To determine the optimized dose of FC for experiment, FC extract at 50, 100, and 200 mg/kg were administered to 3-week rats. Since the effect of FC at 200mg/kg was superior to the others, FC extract of this dosage was daily given to the treatment group for 10 days by oral gavage. Meanwhile, normal saline was administered in the control group, and rhGH of 20 μ g/kg was subcutaneously injected

in the rhGH group, daily. Body weight and food intake were monitored on the 0, 3, 6, and 9th day of the study. On 10th day, 5-bromo-2'-deoxyuridine (BrdU) of 30 mg/kg body weight was intraperitoneally injected, and the subjects were sacrificed after 2 hours.

Micro-computed tomography analysis

Micro-CT (SKyScan 1172 X-ray Microtomograph, Antwerp, Belgium) was utilized to assess the trabecular bone architecture. The proximal tibia was the region of interest because of its rapid growth[9]. The acquired 2D shadow/ transmission images were used to reconstruct the axial cross-sections by SkyScan's cluster reconstruction software (NRecon/NRecon Server). With this program, five variables were obtained: 1) bone volume fraction (ratio of the segmented bone volume to the total volume of the region), 2) bone surface/volume ratio, 3) trabecular thickness (mean thickness of trabeculae), 4) trabecular number (average number of trabeculae per unit length), and 5) trabecular separation (mean distance between trabeculae)[10].

Radiographic measurement of the total tibia length

The radiograph showing the entire tibia length was taken at 55kV/320 μ A, and the bone length was directly measured using a microfilm reader (OM-FORTE-10121, DK medical system, Pyeongtaek, Gyeonggi, Korea). Along the long axis, the distance between the proximal and distal articular lines was measured as the total tibia length.

Histomorphologic examination

While one hind limb of each subject was excised for radiologic analysis, the other leg left was fixed in 4% buffered formalin, decalcified, and embedded in paraffin. Longitudinal sections of 4- μ m-thickness were cut and stained with hematoxylin and eosin.

Assessment of growth plate proliferative activity by BrdU-labeling

BrdU immunohistochemistry was performed according to the manufacturer's protocol for BrdU staining kit (Invitrogen, Carlsbad, CA, USA). In the proliferative zone of the proximal tibial growth plate, total number of the chondrocytes and the number of BrdU-positive chondrocytes were counted using a BX51 microscope (Olympus).

Measurement of serum osteocalcin level

The serum osteocalcin level was measured by enzyme-linked immunosorbent assay with a rat osteocalcin kit (CSB-E05129r from Cusabio Biotech Co, Ltd, China) according to the manufacturer's protocol.

Statistical analysis

The data were presented as mean \pm SD. Differences between groups were analyzed by ANOVA followed by Student's t-test or Tukey's multiple comparison. P value less than 0.05 was considered statistically significant.

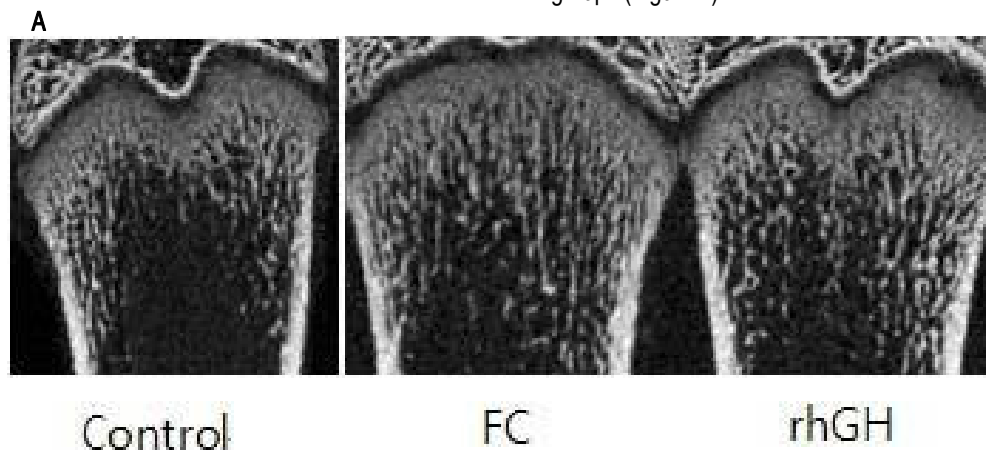
Results and Discussion

Body weight and food intake change

Neither the increase of body mass nor the food intake change in each group was statistically different.

Micro-CT analysis of proximal tibia

All of the evaluated parameters (bone volume fraction, bone surface/volume ratio, the thickness and number of trabeculae, and trabecular separation) revealed no significant difference among the groups (Figure 1).



B

	control	FC	rhGH
Bone volume fraction	28.66	26.09	27.87
Bone surface / volume ratio	32.56	32.06	31.26
Trabecular thickness	0.13	0.13	0.13
Trabecular number	2.20	2.00	2.13
Trabecular separation	0.32	0.34	0.34

Figure 1. Micro-CT analysis of proximal tibia

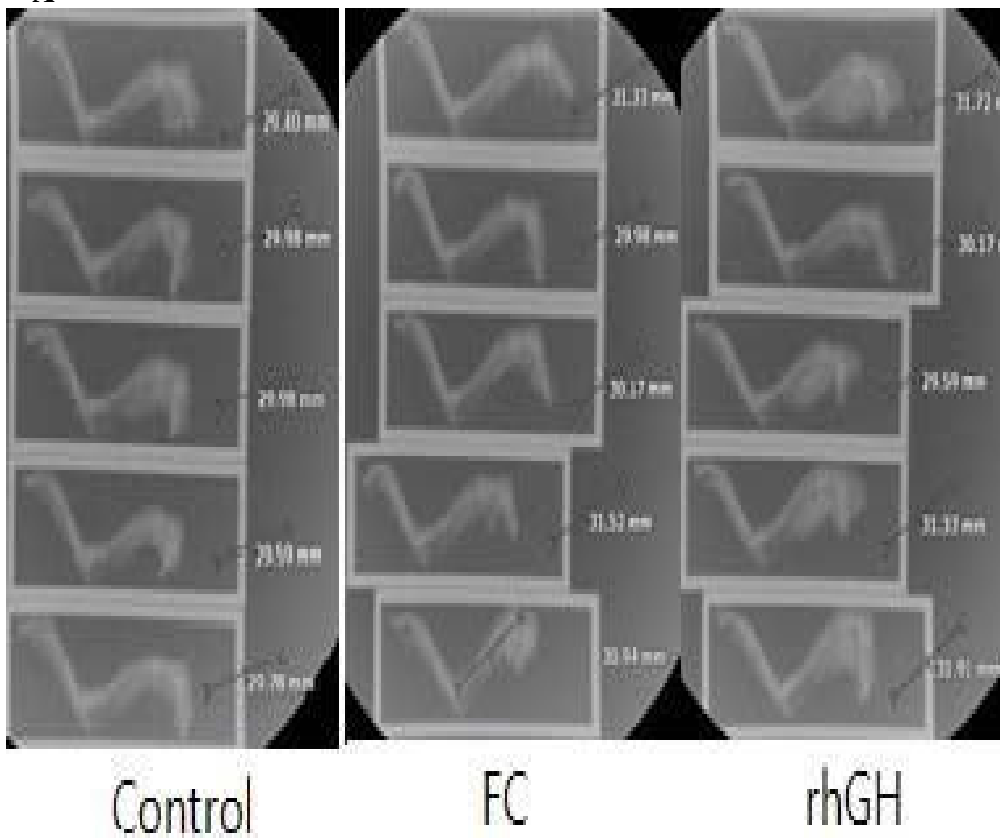
A) Representative micro-CT images of the proximal tibia.

B) The evaluated parameters in micro-CT analysis. Data represent mean. ($p < 0.05$ by paired Student's t-test)

Total tibia length

The total tibia length, measured by radiographic analysis, of the rhGH (30.94 mm) and FC groups (30.78 mm) were significantly increased, compared to the control group (29.75 mm) (Figure 2).

A



B



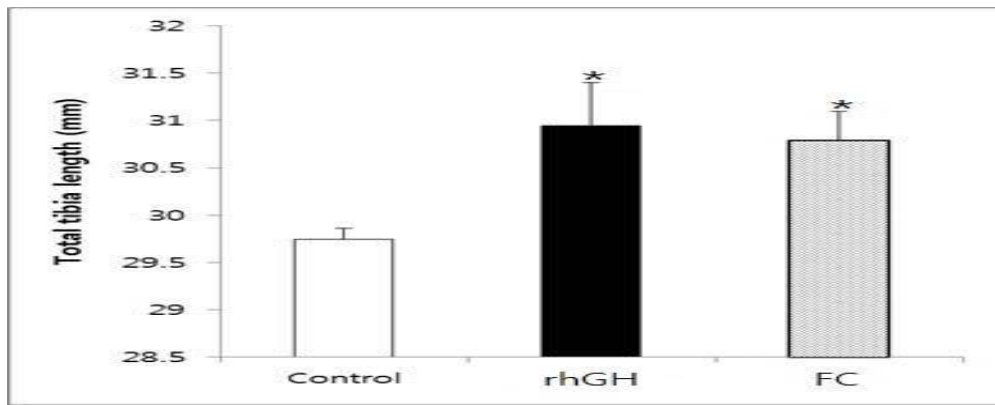


Figure 2. Radiographic measurement of the total tibia length

A) Radiographs show the entire length of tibia.

B) Data represent mean \pm SD (n = 5). ($p < 0.05$ by paired Student's t-test)

Growth plate thickness

Figures 3-5 show the thickness of growth plate in each group. Compared to the proliferative zone thickness of the control group

(0.38 mm), those of the rhGH (0.45 mm) and FC groups (0.42 mm) were increased. The hypertrophic zone thickness also revealed the similar tendency (control: 0.53 mm, rhGH: 0.59 mm, FC: 0.57 mm).

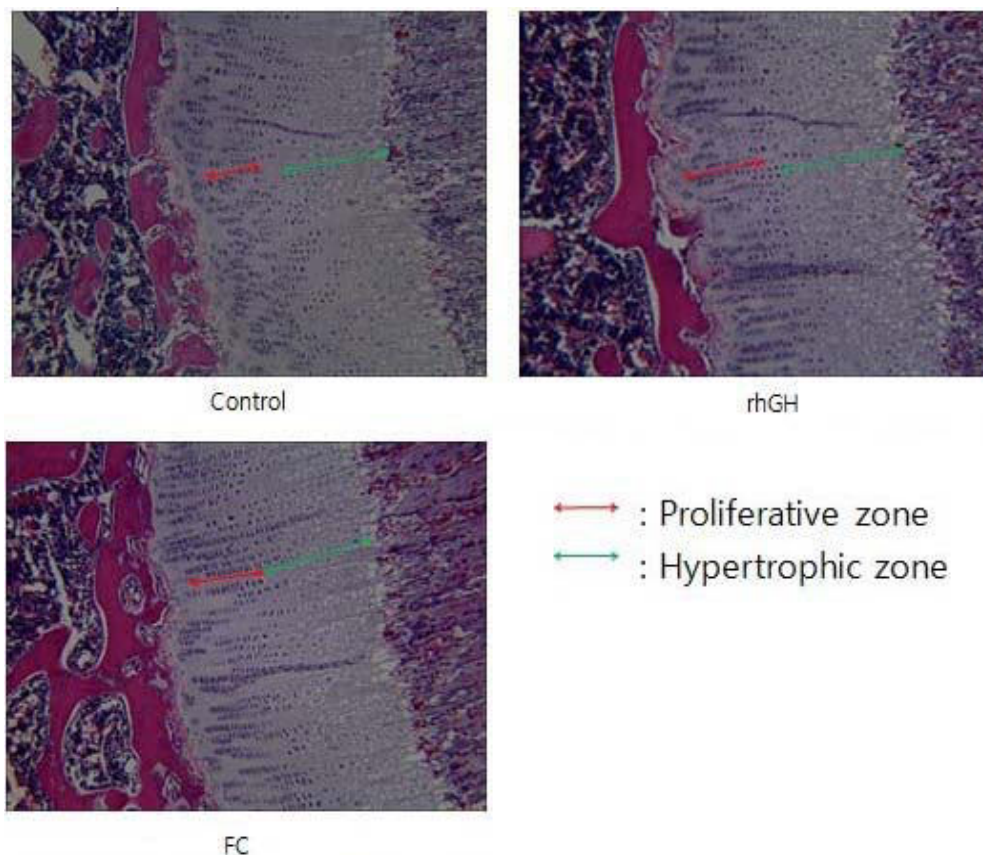


Figure 3. Representative microphotographs of the growth plate (Hematoxylin and Eosin staining, 40x)



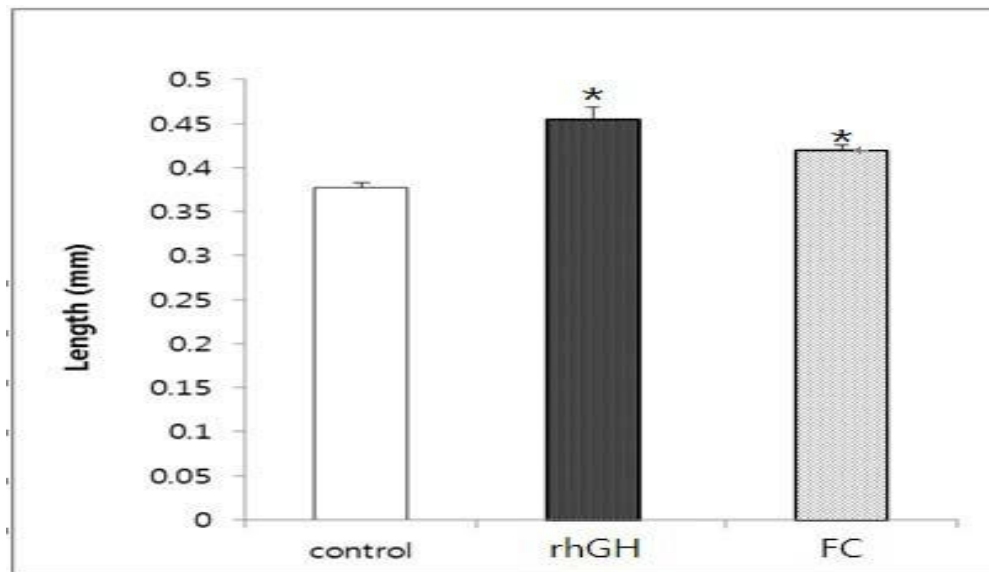


Figure 4. The thickness of the proliferative zone in growth plate

On the microphotographs of growth plate (Figure 3), at least three different areas of the proliferative zone were randomly selected and measured in each specimen. The mean values were

statistically analyzed. Data represent mean \pm SD (n = 5). ($p < 0.05$ by paired Student's t-test)

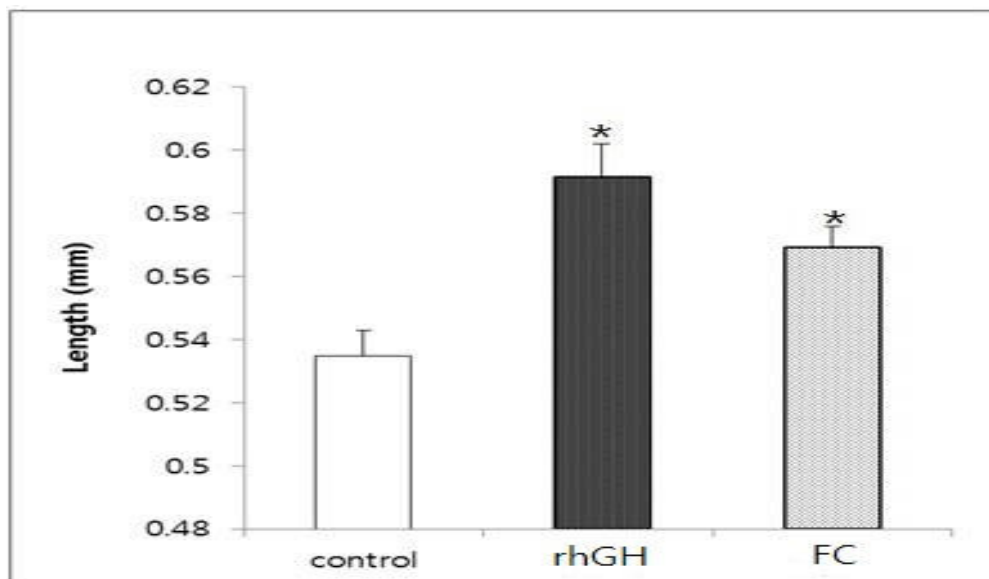


Figure 5. The thickness of the hypertrophic zone in growth plate

On the microphotographs of growth plate (Figure 3), at least three different areas of the proliferative zone were randomly selected and measured in each sample. The mean values were statistically analyzed. Data represent mean \pm SD (n = 5). ($p < 0.05$ by paired Student's t-test)

In the growth plate, proliferating chondrocytes were positively stained with BrdU immunohistochemistry. The BrdU-labeling indexes (the number of BrdU-positive chondrocytes/total number of chondrocytes) of the rhGH (0.22) and FC groups (0.21) were statistically different from that of the control group (0.15) (Figure 6). No significant difference in the value was present between the rhGH and FC groups.

BrdU-labeling index in growth plate



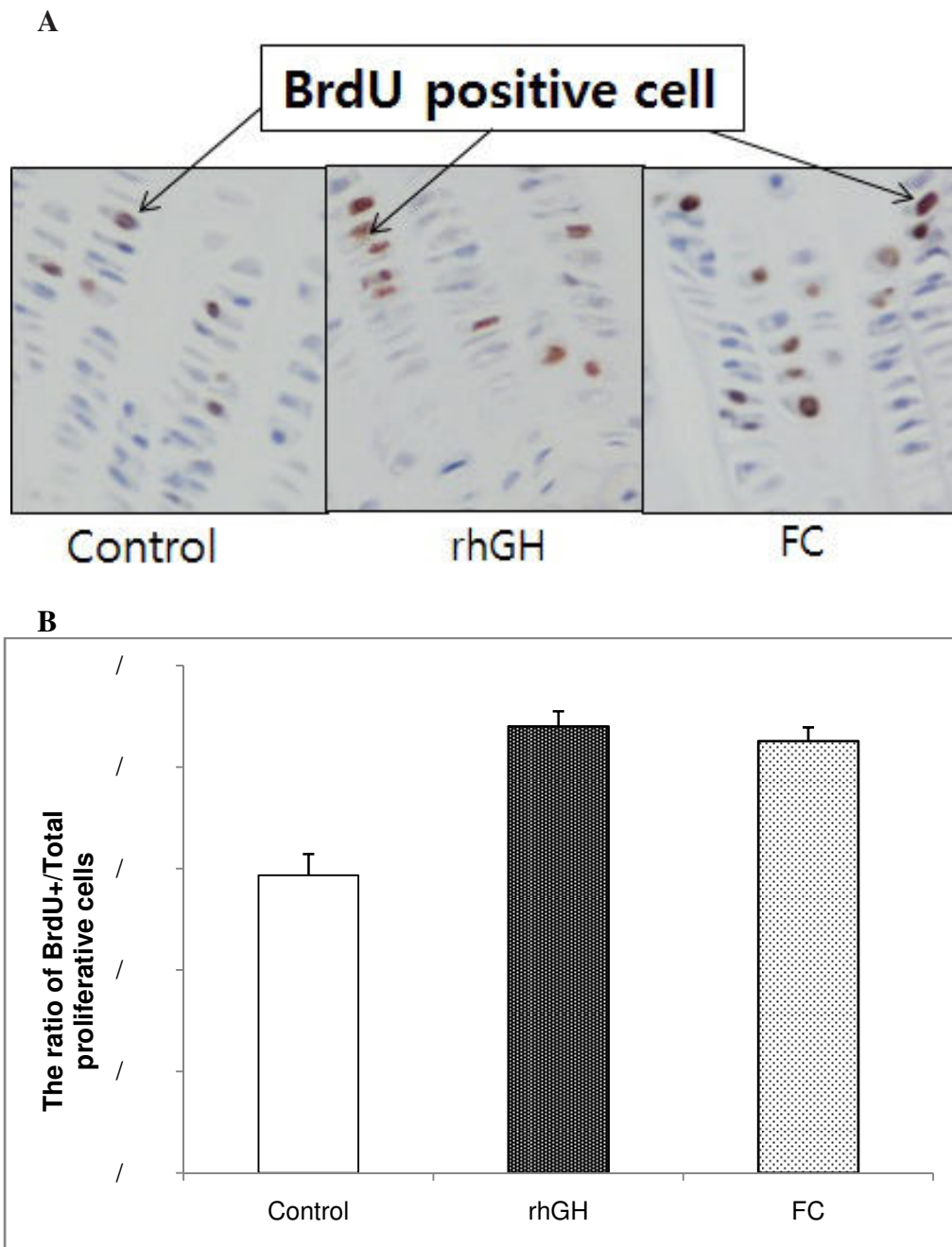


Figure 6. BrdU-labeling in the growth plate

A) Representative images of BrdU-labeled chondrocytes.

B) BrdU-labeling index. Data represent mean \pm SD (n = 5). ($p < 0.05$ by paired Student's t-test)

Serum osteocalcin level

In 10 days of the experiment, serum osteocalcin levels of rhGH group (3.60 ng/mL) and FC group (3.74 ng/mL) were statistically

different from that of the control group (2.83 ng/mL) (Figure 7). No significance difference was present between the rhGH and FC groups.



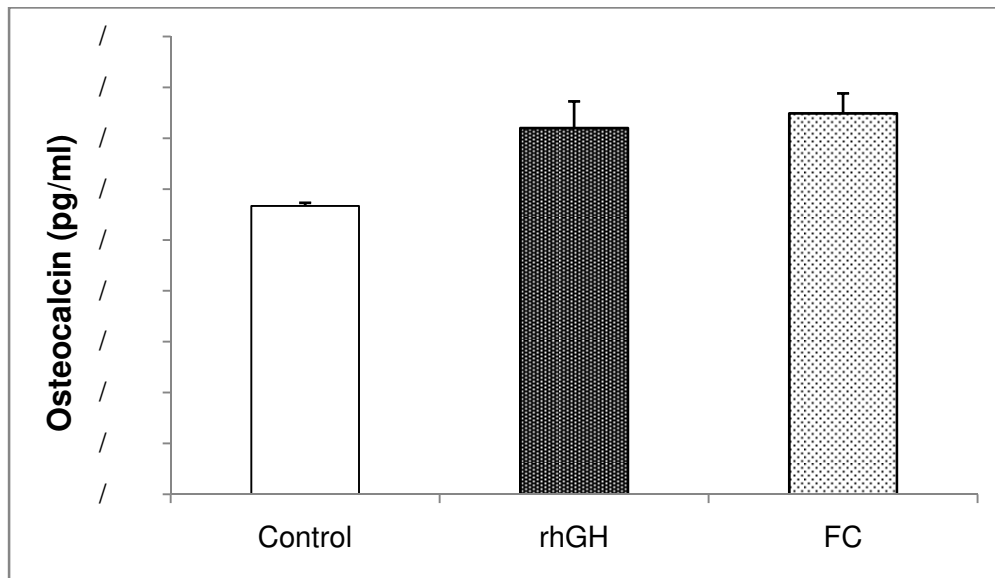


Figure 7. Serum osteocalcin level

Data represent mean \pm SD (n = 5). ($p < 0.05$ by paired Student's t-test)

Discussion

Our data revealed that all of the evaluated factors (physical bone length, histologic evidence of bone growth, immunohistochemically detected proliferation activity, and the serum biomarker of bone formation) of both rhGH and FC groups were significantly different from those of the control group, and this result accounted for the favorable effect of FC on bone growth.

As a method to assess trabecular bone structure, micro-CT, a CT technique with a spatial resolution of 1-100 μ m, is expected to replace histomorphologic examination and enables *in vivo* investigations in small animals[11]. In addition, micro-CT images proved to be useful for investigating trabecular bone pathology, based on measured values, such as the ratio of bone volume to tissue volume, trabecular thickness, and trabecular separation[12]. The result that all of the acquired measurements by analyzing micro-CT images were not significantly different among the groups reflects the absence of a serious hazard in FC treatment.

In long bones of mammals, linear growth occurs at growth plates by endochondral ossification, in which cartilage is formed and remodeled into bone[13]. The growth plate consists of ordered columns of chondrocytes and is divided into three distinct zones: reserve zone, proliferative zone, and hypertrophic zones (in order from epiphysis to diaphysis)[14]. Chondrocytes in the reserve zone begin to proliferate, differentiate into the hypertrophic zone, and finally undergo apoptosis[15]. Since then, the newly formed cartilage matrix is infiltrated by blood vessels, degraded, and replaced with bone matrix produced by osteoblasts[15]. Not only the total growth plate thickness but also the height of proliferative and hypertrophic zones correlates with the growth rate[16]. In this

regard, it is evident that FC enhanced bone growth as the widening of both proliferative and hypertrophic zones was demonstrated in the rhGH and FC groups, along with the elongated total tibia length.

Estimating the proliferative activity of cells, BrdU, a thymidine analogue, is considered a standard method by measuring the fraction of S-phase cells. Uptake of this chemical is restricted to the cells in S-phase of the cell cycle and can be easily observed by immunohistochemistry[17]. In this study, BrdU-labeling indexes of the rhGH and FC groups were significantly higher than that of the control group. This result indicates that FC induced the chondrocytes of growth plate to proliferate, leading to longitudinal bone growth.

Serum osteocalcin increases as the growth rate is elevated, it is a sensitive marker of bone formation[18]. In our study, serum osteocalcin level was increased in both rhGH and FC groups, and it can be inferred that FC stimulates bone growth by affecting osteoblasts.

Conclusion

As described above, our results support the beneficial effect of FC on longitudinal bone growth. In spite of relatively short period of experiment time with animal subjects, the potentiality of FC to be another strategy to increase the physical height emerged. To investigate the mechanism of action and long-term effects of FC, further studies are required.



References

- [1]. Leschek EW. et al., Effect of growth hormone treatment on adult height in peripubertal children with idiopathic short stature: a randomized, double-blind, placebo-controlled trial. *J Clin Endocrinol Metab*, 2004. 89(7): p. 3140-8.
- [2]. Richmond E , Rogol AD. Current indications for growth hormone therapy for children and adolescents. *Endocr Dev*, 2010. 18: p. 92-108.
- [3]. Souza FM, Collett-Solberg PF. Adverse effects of growth hormone replacement therapy in children. *Arq Bras Endocrinol Metabol*, 2011. 55(8): p. 559-65.
- [4]. Guyda HJ. Growth hormone therapy for non-growth hormone-deficient children with short stature. *Curr Opin Pediatr*, 1998. 10(4): p. 416-21.
- [5]. Sancheti S, Sancheti S, Seo SY. Antidiabetic and antiacetylcholinesterase effects of ethyl acetate fraction of *Chaenomeles sinensis* (Thouin) Koehne fruits in streptozotocin-induced diabetic rats. *Exp Toxicol Pathol*, 2013. 65(1-2): p. 55-60.
- [6]. Oku H, Ueda Y, Ishiguro K. Antipruritic effects of the fruits of *Chaenomeles sinensis*. *Biol Pharm Bull*, 2003. 26(7): p. 1031-4.
- [7]. Miao MS. et al., [Effect of *Phragmites communis* polysaccharide on the aged-model mice]. *Zhongguo Zhong Yao Za Zhi*, 2004. 29(7): p. 673-5.
- [8]. Zhang YW, Wu CY, Cheng JT. Merit of *Astragalus* polysaccharide in the improvement of early diabetic nephropathy with an effect on mRNA expressions of NF-kappaB and I kappaB in renal cortex of streptozotocin-induced diabetic rats. *J Ethnopharmacol*, 2007. 114(3): p. 387-92.
- [9]. Wilsman NJ. et al., Differential growth by growth plates as a function of multiple parameters of chondrocytic kinetics. *J Orthop Res*, 1996. 14(6): p. 927-36.
- [10]. Boussein ML. et al., Guidelines for assessment of bone microstructure in rodents using micro-computed tomography. *J Bone Miner Res*, 2010. 25(7): p. 1468-86.
- [11]. Genant HK, Engelke K, Prevrhal S. Advanced CT bone imaging in osteoporosis. *Rheumatology (Oxford)*, 2008. 47 Suppl 4: p. iv9-16.
- [12]. Yang J, Pham SM, Crabbe DL. High-resolution Micro-CT evaluation of mid-to long-term effects of estrogen deficiency on rat trabecular bone. *Acad Radiol*, 2003. 10(10): p. 1153-8.
- [13]. Hunziker EB. Mechanism of longitudinal bone growth and its regulation by growth plate chondrocytes. *Microsc Res Tech*, 1994. 28(6): p. 505-19.
- [14]. Villemure I, Stokes IA. Growth plate mechanics and mechanobiology. A survey of present understanding. *J Biomech*, 2009. 42(12): p. 1793-803.
- [15]. Brandau O. et al., Chondromodulin I is dispensable during enchondral ossification and eye development. *Mol Cell Biol*, 2002. 22(18): p. 6627-35.
- [16]. Wilsman NJ. et al., Cell cycle analysis of proliferative zone chondrocytes in growth plates elongating at different rates. *J Orthop Res*, 1996. 14(4): p. 562-72.
- [17]. Zacchetti A. et al., Validation of the use of proliferation markers in canine neoplastic and non-neoplastic tissues: comparison of KI-67 and proliferating cell nuclear antigen (PCNA) expression versus *in vivo* bromodeoxyuridine labelling by immunohistochemistry. *APMIS*, 2003. 111(3): p. 430-8.
- [18]. Kanzaki S. et al., Serum propeptide and intact molecular osteocalcin in normal children and children with growth hormone (GH) deficiency: a potential marker of bone growth and response to GH therapy. *J Clin Endocrinol Metab*, 1992. 75(4): p. 1104-9.