

Chemopreventive effects of pomegranate fruit extract on acrylamide induced lung, liver and testis carcinogenesis in male laka mice

Manjhi J¹, Sinha A¹, Ganger R², Rai DV^{1, 2}, Gupta VK³

*Corresponding author:

Manjhi J

¹Centre for Biomedical Engineering, Shobhit University, NH-58, Modipuram, Meerut-250110, India.

²Department of Biophysics, Panjab University, Sector 14, Chandigarh – 160014, India.

³Department of Biochemistry, All India Institute of Medical Sciences, New Delhi

Abstract

The present study was aimed to test the efficacy of pomegranate fruit extract to induce apoptosis in the artificially induced tumor cells in mice. Method: Adult male LAKA-UK mice (30-40g) were divided into four groups, viz. control, AA, PFE and PFE+AA. Induction of carcinogenesis by intra-peritoneal administration of acrylamide was preceded by PFE treatment in PFE+AA group. At the end of study animals were sacrificed by decapitation under deep anesthesia and organs (lung, liver and testes) were resected to evaluate activities of various enzymes such as CAT, SOD, GPx, GSH and GST in different experimental groups. MTT assay and histological examination of lung and liver sections were also conducted. Result: Administration of acrylamide resulted in the increase SOD, GPx and GSH activities, which decreased significantly ($p < 0.05$) in PFE+AA group. The MTT assay showed high cell proliferation in the AA group of mice which lessened in treatment groups. Similarly the histological examinations exhibited alveolar wall destruction and air space enlargement in pulmonary tissues and larger vacuolization in the hepatic tissues due to acrylamide administration, whereas in PFE+AA cells it was found to be normal. Conclusion: Pomegranate fruit extract was observed to be a potential treatment intervention that not only prevents the onset and progress of carcinogenesis but also helps in the initiation of apoptosis and refurbishment of the damaged cellular architecture.

Keywords: Acrylamide, Carcinogenesis, Catalase, Glutathione peroxidase, Glutathione-S-transferase, Pomegranate Fruit Extract, Superoxide dismutase

Introduction

Cancer is a leading cause of death worldwide. Lung cancer as the most common fatal neoplastic disease in the world responsible for 28% of all the cancer related deaths.[1] Primary liver cancer is the sixth most common cancer in the world and the third most common cause of cancer mortality.[2] Testicular cancer is uncommon in most countries with an incidence that ranges from, 10 to 100 per million and accounts for, 1% of all cancers in men but, 60% of all cancers in young males 15–35 years of age. Moreover, the incidence of testicular cancer has doubled in the last 20–40 years.[3, 4]

Acrylamide is a naturally occurring white crystalline chemical compound at room temperature found in many plant-based, high-carbohydrate foods after they are heated and is classified by the International agency for research on cancer (IARC) as a probable human carcinogen. Acrylamide reactivity with enzymes or receptors may induce changes in cellular functions and signal pathways, leading to a possible involvement with acrylamide induced carcinogenesis.[5] There is robust evidence available in the literature to support of positive dose response relationships between acrylamide exposure and cancer in multiple organs and tissues in animal model.[6–9]

Pomegranate (*Punica granatum*, Punicaceae), native to Persia, is an edible fruit cultivated in Mediterranean countries, Afghanistan, India, China, Japan, Russia, and some parts of the United States. Edible parts of pomegranate fruit (80% of total fruit weight) are comprised of 80% juice and 20% seed.[10] Pomegranate fruit is a rich source of two types of polyphenolic compounds: anthocyanins (such as delphinidin, cyanidin, and pelargonidin), which give the fruit and juice its red color; and hydrolyzable tannins (such as punicalin, pedunculagin, punicalagin, gallagic, and ellagic acid esters of glucose), which account for 92% of the antioxidant activity of the whole fruit.[11,12] The hydrolyzable tannins account for 92% of the antioxidant activity of the whole fruit.[13] The soluble polyphenol content in pomegranate juice varies between 0.2 and 1.0%.[14] Dietary supplementation of polyphenol-rich pomegranate juice to atherosclerotic mice was shown to inhibit significantly the development of atherosclerotic lesions.[15]

Chemoprevention is an effective strategy to control the incidence of cancer and is a pharmacological approach to intervention in order to arrest or reverse the process of carcinogenesis.[16] Extracted edible seeds of pomegranate fruit with acetone, referred as pomegranate fruit extract (PFE). Studies in animal models of cancer suggest that PFE consumption may be anti-carcinogenic[17,18] and can be a useful chemopreventive agent against human lung cancer.[19] Phytochemicals from fruit

pomegranate may inhibit cancer cell proliferation and apoptosis through the modulation of cellular transcription factors and signaling proteins.[20] Oral administration of PFE to A/J mice significantly inhibited lung carcinogen-induced NF-kappaB and IKK alpha, transcription factors that play a central role in several cellular processes, including proliferation, cell adhesion, apoptosis, inflammatory response, and regulation of the immune response.[21]

In view of available literature the present study was designed to investigate the chemopreventive effects of Pomegranate fruit extract on acrylamide induced lung, testis and liver carcinogenesis in male Laka mice. For studying the effect of acrylamide on antioxidant status, the activities of enzymic antioxidants SOD, CAT, GPx, GST and non-enzymic antioxidant GSH were measured.

Materials and methods

Animals

Normal adult male LAKA-UK mice (30-40g) were procured from central experimental animal facility of Panjab University, Chandigarh. They were housed in polypropylene cages at 25 ± 2 C, relative humidity $50 \pm 15\%$ and normal photo period (12 hr dark/12 hr light) were used for the experiment. Commercial pellet diet containing and water were provided *ad libitum*. Commercial pellet diet (Ashirwad, Punjab, India) contains protein: 24%, fat: 5%, fiber: 4%, carbohydrate: 55%, calcium: 0.6%, phosphorous: 0.3%, moisture: 10% and ash: 9% w/w. Animals were acclimatized for the period of one week.

Study Design

Mice (n=40) were equally divided into the following four experimental groups containing 10 animals each: control group, acrylamide group (AA), pomegranate fruit extract group (PFE) and acrylamide + pomegranate fruit extract group (PFE+AA). Carcinogenesis was induced in animals of group AA and PFE+AA, by the intra-peritoneal injections acrylamide at a dose of 50 mg/Kg body weight in 0.25 ml of deionized water, three times a week for 8 weeks. Animals of control and PFE groups received normal diet with tap water *ad libitum* and pomegranate fruit extract (0.2% w/v) respectively. After the completion of study the animals were sacrificed by decapitation under deep anesthesia and their lungs, liver and testes were resected for further biochemical and histological analyses.

Induction of Carcinogenesis and Treatment

Carcinogenesis was induced in the mice of Group AA by intra-peritoneal administration of acrylamide at a dose of 50 mg/Kg body weight in 0.25 ml of deionized water, three times a week for 8 weeks. In PFE+AA group, the animals were fed on pomegranate fruit extract (0.2% w/v) in drinking water for one week and then subjected to acrylamide injection similar to the AA group. The administration of pomegranate juice resumed thereafter till the end

of the experiment. Animals in the PFE group were given pomegranate fruit extract (0.2% w/v) in drinking water till the end of experiment. The study was approved by Institutional Animal Ethical Committee, Panjab University, Chandigarh, India.

Sample preparation

Animals were fasted overnight and sacrificed by decapitation. The organs (lung, liver and testes) were removed, washed with normal saline and 10% homogenate was prepared in potassium phosphate buffer (100mM, pH 7.5). The homogenates were centrifuged at 800 g for 5 minutes at 4 C to separate the nuclear debris. The supernatant so obtained was centrifuged at 10,500 g for 20 minutes at 4 C to get the post mitochondrial supernatant (PMS) which was used to various biochemical assays.

Biochemical Analysis

Various enzymes such as CAT, SOD, GPx, GSH and GST were assayed before and after the induction of carcinogenesis by acrylamide administration and PFE treatment. The values of enzyme activity obtained were used to evaluate the variations in percentage of the enzymes in different experimental groups (viz. Control, AA, PFE, PFE+AA) which surfaced the enzymatic manipulations in the carcinogenic and recovering cells. The percentage variations were calculated by dividing the change in enzyme activity of a group with respect to a baseline group (Control or AA) to baseline group, multiplied by 100.

Assay of Catalase (CAT) and superoxide dismutase (SOD)

CAT was assayed colorimetrically at 240 nm and expressed as mM of H_2O_2 consumed/min/mg protein[22] as described by Luck, 1965. 1.5 ml of the H_2O_2 buffer added 20 μ l of sample supernatant (PMS). H_2O_2 catalyzed by this enzyme was measured by decrease in absorbance at 240 nm, taking 0.0394 mM-1cm-1 extinction coefficient and enzyme activity was expressed as K/mg protein. Here "K" is the first order rate constant.

SOD was assayed utilizing the technique of Kono and Fridovich, 1982 based on inhibitory effect of SOD on the reduction of NBT (Nitroblue tetrazolium) dye by superoxide anions which are generated by the photo-oxidation of hydroxylamine hydrochloride.[23] Rate of reduction was noted at 560 nm. A single unit of enzyme was expressed as 50% inhibition of NBT reduction/min/mg protein.

Determination reduced glutathione (GSH) and glutathione peroxidase (GPx)

GSH was determined by the method of Moron *et al.*, 1979. [24] 100 μ l of PMS (10 %) was precipitated with 25 μ l of 25% trichloroacetic acid and the precipitate was removed by centrifugation at 1500 x g for 10 min. 50 μ l of the supernatant was added to 450 μ l of phosphate buffer and 1 ml of 0.6 mM DNTB. The absorbance was

read at 412 nm. Reduced glutathione was expressed as micromole of GSH/mg protein of tissue.

GPx activity was measured by the method described by Paglia and Valantine, 1987. [25] Briefly, reaction mixture contained 820 μ l phosphate buffer pH 7.0, 37.5 μ l H₂O₂ and 25 μ l of PMS. The decrease in absorbance due to NADPH oxidation was monitored at 340 nm for 3 min. One unit of enzyme is defined as nmol NADPH consumed/min/mg protein using an extinction coefficient of 6.22 mM⁻¹cm⁻¹.

Determination of glutathione-S-transferase (GST)

The GST activity was determined spectrophotometrically [26] by the method of Habig et al., 1981. The reaction mixture (3 ml) contained 2.7 ml of 100 mM phosphate buffer, 0.1 ml of 30 mM 1-chloro-2, 4 - dinitrobenzene (CDNB) and 0.1 ml of 30 mM GSH. After preincubating the reaction mixture at 37 C for 2 min, the reaction was started by the addition of 0.1 ml of 10% PMS and the increase in absorbance was followed for 3 min at 340 nm. Reaction mixture without the enzyme was used as blank. The activity of GST is expressed as μ moles of GSH-CDNB conjugate formed/min/mg protein using an extinction coefficient of 9.6 mM⁻¹ cm⁻¹

Estimation of protein

Protein was determined by the method of Lowry et al., 1951 using Bovine Serum Albumin (BSA) as standard, at 660 nm. [27]

MTT assay

The MTT-test for cell proliferation was performed as described by Supino, 1990, using incubation times of 24 and 48 hr. [28] In brief, lung, liver and testis were perfused, enzymatically digested and single cell suspensions were made in Ca and Mg free phosphate buffered saline (PBS, Gibco, USA) 5 g/L. This suspension was centrifuged and the precipitate was resuspended in MTT (3-(4,5-dimethylthiazol-2-yl)-2,5-diphenyl tetrazolium bromide, Sigma), dissolved in Ca- and Mg-free phosphate buffered saline (PBS, Gibco, USA). Sample cells (105cells/100 μ l) were incubated at 5% CO₂ and 37 C for 24 and 48 hrs in multiwell tissue culture plates (96 well/plate). After centrifugation of the plates at 2000 rpm for 10 min, incubation medium was aspirated and replaced with dimethylsulphoxide (DMSO, Merck, Darmstadt, Germany), shaken

for 5 min and the absorbances were measured at 550 nm (reference at 620 nm) in a microculture plate reader.

Histological Analysis

Light microscopic study

Histological analysis of lung and liver tissue sections were done with the standard method. Tissue samples were fixed in 10% formalin, routinely processed and embedded in paraffin. Paraffin sections (5 μ m) were cut on glass slides and stained with hematoxylin and eosin (H&E) and examined under a light microscope.

Statistical Analysis

All values are expressed as mean \pm SE. One way ANOVA was applied to test for significance of biochemical data of the different groups. Data is represented as Mean \pm SD (n=10). Data is analyzed by using one way ANOVA post Hoc test using least significance difference (LSD) and by student's 't' test at p=0.05 using SPSS statistical software. Significance is set at p < 0.05.

Results

The chemopreventive and anticarcinogenic effect of PFE on development of lung, testis and liver tumors induced by acrylamide administration were assessed.

CAT Activity

The CAT activity in the different types of tissues viz. lungs, liver and testes were measured. Administration of Acrylamide (AA) caused insignificant increase (+17.50%) in the pulmonary CAT, however, a significant (p<0.01) decrease in the CAT level was observed in the hepatic (-49.14%) and testicular (-49.61%) tissues as compared to the control group (Table 1). After treatment, the PFE+AA group mice exhibited an insignificant decrease in the pulmonary and hepatic CAT levels and also significant (p<0.05) increase (+66.14%) in the testicular CAT levels when compared to the group exposed to AA only (Figur1).

Table 1: Percentage Variation in Cat Activity due to Acrylamide Induction and PFE Treatment in Different Tissues (viz. Lung, Liver and Testes)

GROUPS	LUNG		LIVER		TESTES	
	Enzyme Activity (mMolH ₂ O ₂ /min/mg decomposed)	% Change	Enzyme Activity (U/ml)	% Change	Enzyme Activity (U/ml)	% Change
I (Control)	66.96 \pm 13.95	-	59.34 \pm 15.87	-	59.6 \pm 15.71	-
II (AA)	78.68 \pm 12.56	+17.50*	30.18 \pm 7.17	-49.14*	30.03 \pm 6.47	-49.61*
III (PFE)	48.26 \pm 0.33	+27.93*	14.66 \pm 8.62	-75.29*	75.3 \pm 15.47	+26.34*
IV (PFE+AA)	75.88 \pm 30.24	-3.55\$	6.73 \pm 3.86	-77.70\$	49.89 \pm 20.33	+66.14\$

*w.r.t. Group I (Control)

\$w.r.t Group II (AA)

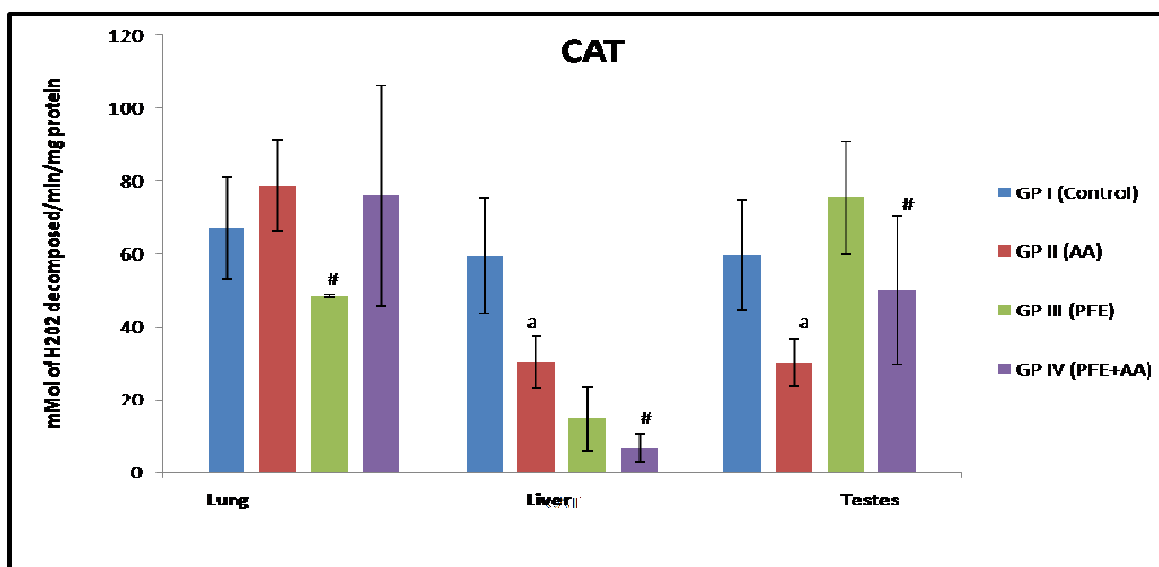


Figure 1: Variations in CAT levels in different tissues (Pulmonary, Hepatic and Testicular) of mice upon treatment with Acrylamide and PFE

#: p 0.05 significant as compared to AA group
 a: p 0.01 significant as compared to control group

SOD Activity

The administration of Acrylamide (AA) caused insignificant increase in the pulmonary SOD levels, however, an insignificant decrease in SOD level was noted in the hepatic tissues. In the testicular tissues the SOD activity enhanced (+150.0%)

significantly (p<0.01) as compared to the control group (Table 2). After treatment, the PFE+AA group mice exhibited a significant decrease in the pulmonary and testicular SOD level while in the hepatic tissues it was observed to be enhanced (+119.62%) as shown in Figure 2.

Table 2: Percentage Variation in SOD Activity due to Acrylamide Induction and PFE Treatment in Different Tissues (viz. Lung, Liver and Testes)

Groups	LUNG		LIVER		TESTES	
	Enzyme Activity (U/mg)	% Change	Enzyme Activity (U/ml)	% Change	Enzyme Activity (U/ml)	% Change
Gp I (Control)	0.295±0.071	-	0.29±0.018	-	0.24±0.23	-
GP II (AA)	0.33±0.14	+11.86*	0.27±0.033	-6.89*	0.6±0.3	+150.0*
GP III (PFE)	0.245±0.07	-17.01*	0.28±0.088	-3.44*	0.317±0.017	+32.08*
GP IV (PFE+AA)	0.23±0.095	-30.30\$	0.613±0.416	+119.62\$	0.261±0.03	- 56.66\$

*w.r.t. Group I (Control)
 \$w.r.t Group II (AA)

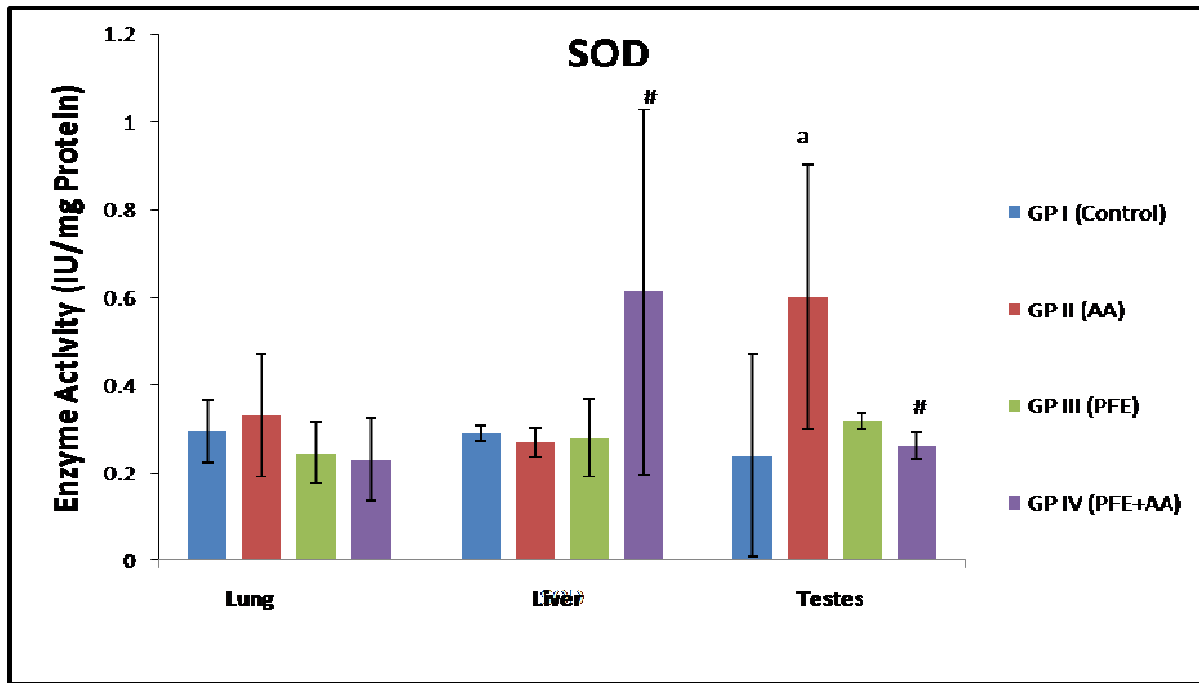


Figure 2: Variations in SOD levels in different biological (Pulmonary, Hepatic and Testicular) tissues of mice upon treatment with Acrylamide and PFE

a: p 0.01 significant as compared to control group
 #: p 0.05 significant as compared to AA group

GPx Activity

The GPx activity in the pulmonary and hepatic cells was insignificantly increased with acrylamide administration as compared to control. However, this increase was significant (p<0.01) in testicular tissues (+341.66%). The GPx level of PFE group was found to be highest in pulmonary tissues (+290%). On

the other hand, in the PFE+AA treated mice, a significant (p<0.05) increase in the hepatic (+126%) and testicular (52.83%) GPx levels were verified, in comparison to AA groups of mice (Figure 3). The pulmonary tissues exhibited a reduced GPx activity, compared to both AA group and control (Table 3).

Table 3: Percentage Variation in GPx Activity due to Acrylamide Induction and PFE Treatment in Different Tissues (viz. Lung, Liver and Testes)

Groups	LUNG		LIVER		TESTES	
	Enzyme Activity (µmol NADPH Oxidised/min/mg)	% Change	Enzyme Activity (U/ml)	% Change	Enzyme Activity (U/ml)	% Change
I (Control)	0.2±0.114	-	0.16±0.1	-	0.12±0.18	-
II (AA)	0.23±0.03	+15.0*	0.23±0.12	+43.75*	0.53±0.08	+341.66*
III (PFE)	0.78±0.2	+290*	0.13±0.16	-18.75*	0.198±0.001	+66.67*
IV (PFE+AA)	0.17±0.11	-26.08\$	0.52±0.24	+126.08\$	0.81±0.27	+52.83\$

*w.r.t. Group I (Control)

\$w.r.t Group II (AA)



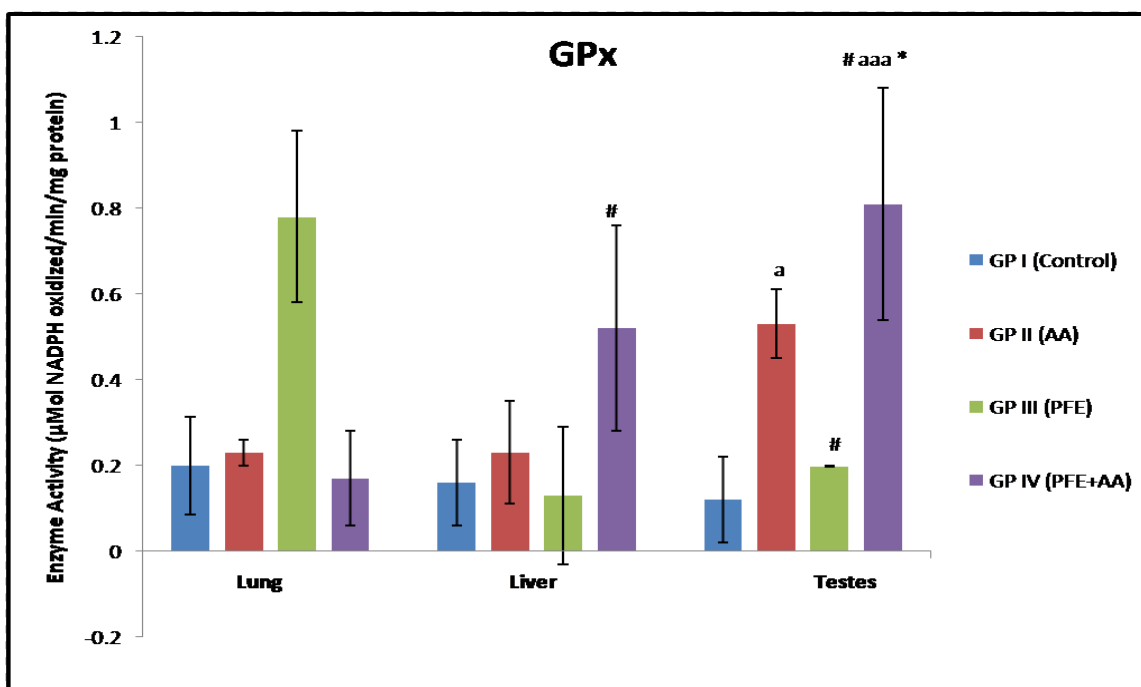


Figure 3: Variations in GPx levels in different biological (Pulmonary, Hepatic and Testicular) tissues of mice upon treatment with Acrylamide and PFE

a: p 0.01 significant as compared to control group
 #: p 0.05 significant as compared to AA group
 aaa: p 0.001 significant as compared to PFE group

GSH Activity

The administration of acrylamide caused significant (p<0.05) increase in the pulmonary (+50.40%) and testicular GSH levels (+64.53%). In the hepatic tissues the GSH level decreased in AA

treated mice. Upon treatment with PFE prior to AA administration, i.e in PFE+AA group of mice, significant (p<0.05) increase (+135.97%) in the hepatic GSH levels were recorded when compared to AA group of mice. The GSH activity in pulmonary tissues decreased (-58.87) significantly (p<0.05) in comparison to AA group (Table 4, Figure 4).

Table 4: Percentage Variation in GSH Activity due to Acrylamide Induction and PFE Treatment in Different Tissues (viz. Lung, Liver and Testes)

Groups	LUNG		LIVER		TESTES	
	Enzyme Activity (µmol/min/mg)	% Change	Enzyme Activity (U/ml)	% Change	Enzyme Activity (U/ml)	% Change
I (Control)	13.71±5.69	-	13.47±5.31	-	18.47±7.46	-
II (AA)	20.62±7.73	+50.40*	7.7±1.0	-42.83*	30.39±0.73	+64.53*
III (PFE)	9.09±0.81	-33.70*	6.77±0	-49.74*	9.37±0.73	-49.26*
IV (PFE+AA)	8.48±2.17	-58.87\$	18.17±13.39	+135.97\$	19.83±13.83	-34.75\$

*w.r.t. Group I (Control)
 \$w.r.t Group II (AA)

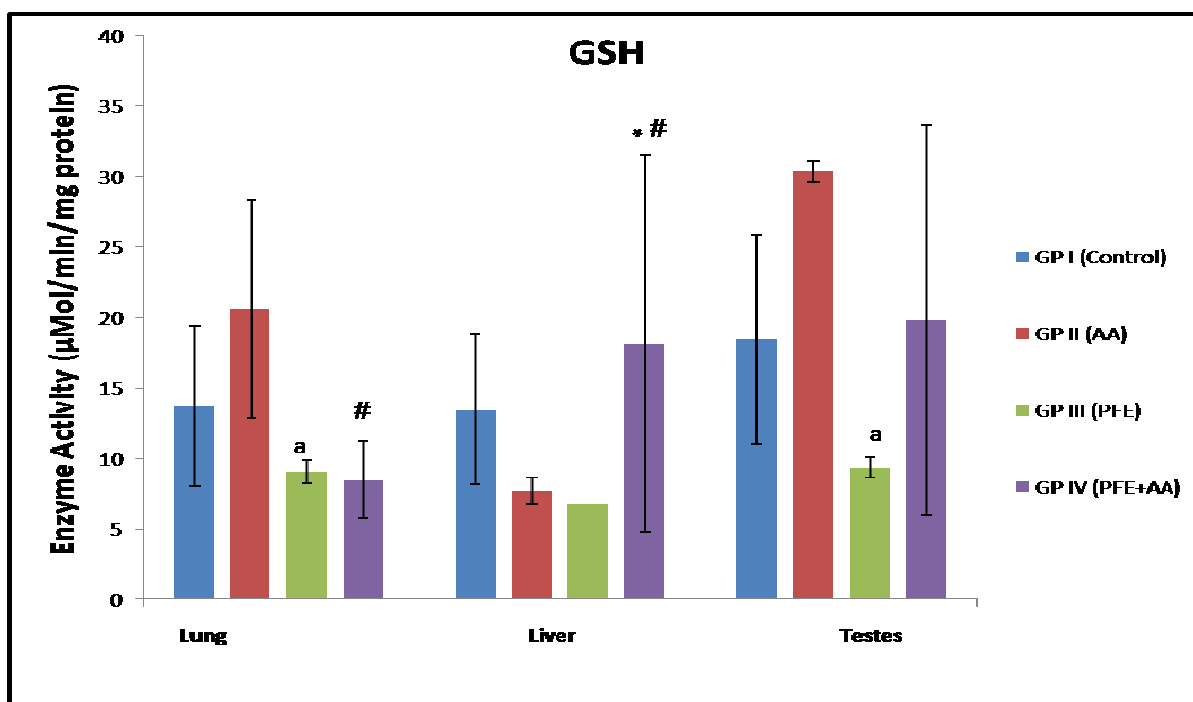


Figure 4: Variations in GSH levels in different biological (Pulmonary, Hepatic and Testicular) tissues of mice upon treatment with Acrylamide and PFE

a:p 0.01 significant as compared to AA group
 *:p 0.05 significant as compared to control group
 #:p 0.05 significant as compared to AA group

GST Activity

The GST activity in the acrylamide treated group was found to enhance insignificantly in the pulmonary, testicular and hepatic tissues when compared to the control group. The Treatment group (PFE) exhibited a much reduced GST activity in all types of tissues.

In the treatment group i.e. PFE+AA also there was a significant (p<0.05) decrease in the GST activity as compared to AA group in all the tested tissue samples including pulmonary (-48.91%) and hepatic (-53.30%) (Table 5, Figure 5).

Table 5: Percentage Variation in GST Activity due to Acrylamide Induction and PFE Treatment in Different Tissues (viz. Lung, Liver and Testes)

Groups	LUNG		LIVER		TESTES	
	Enzyme Activity (µmol/min/mg)	% Change	Enzyme Activity (U/ml)	% Change	Enzyme Activity (U/ml)	% Change
I (Control)	2.11±1.98	-	5.37±2.86	-	4.81±1.15	-
II (AA)	2.31±1.5	+9.47*	6.06±3.31	+12.85*	5.37±1.78	+11.64*
III (PFE)	1.03±0.97	-51.18*	3.35±2.92	-37.61*	4.38±1.29	-8.94*
IV (PFE+AA)	1.18±0.75	-48.91\$	2.83±1.33	-53.30\$	4.99±1.65	-7.07\$

*w.r.t. Group I (Control)
 \$w.r.t Group II (AA)

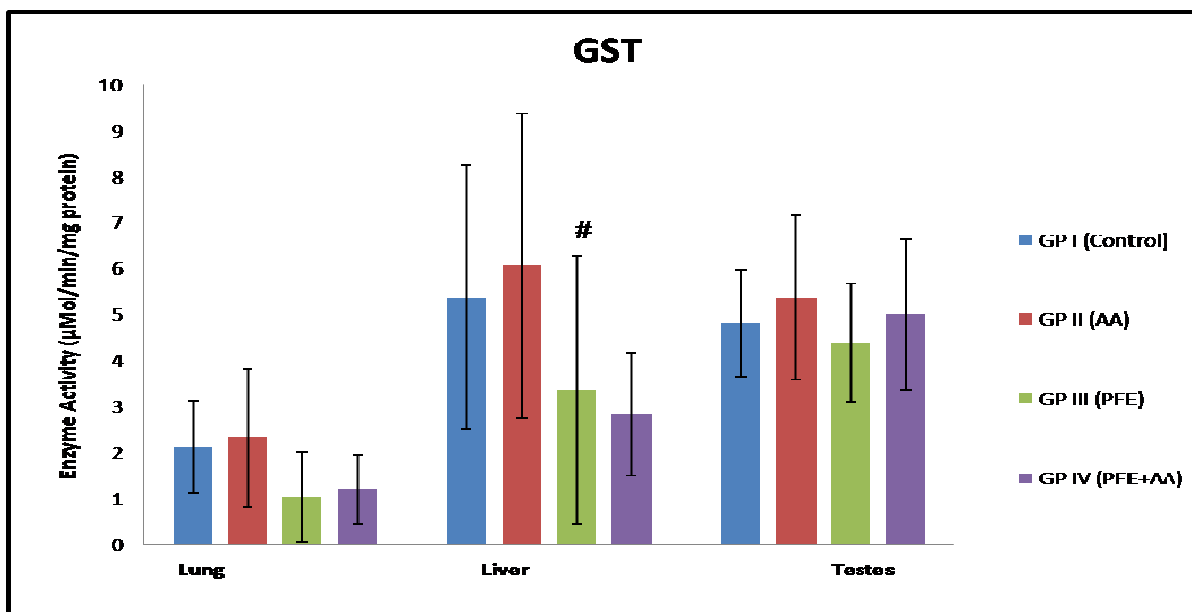


Figure 5: Variations in GST levels in different biological (Pulmonary, Hepatic and Testicular) tissues of mice upon treatment with Acrylamide and PFE

#: p 0.05 significant as compared to AA group

MTT Assay

MTT assay showed that AA markedly induced cellular proliferation in lung, testis and liver. But in case of liver, there was more proliferation after 24 hrs which then decreased after 48 hrs in AA

treated mice. PFE administration caused a decrease in cellular proliferation in conjunctive group than AA treated group after 24 hrs and 48 hrs (Figure 6).

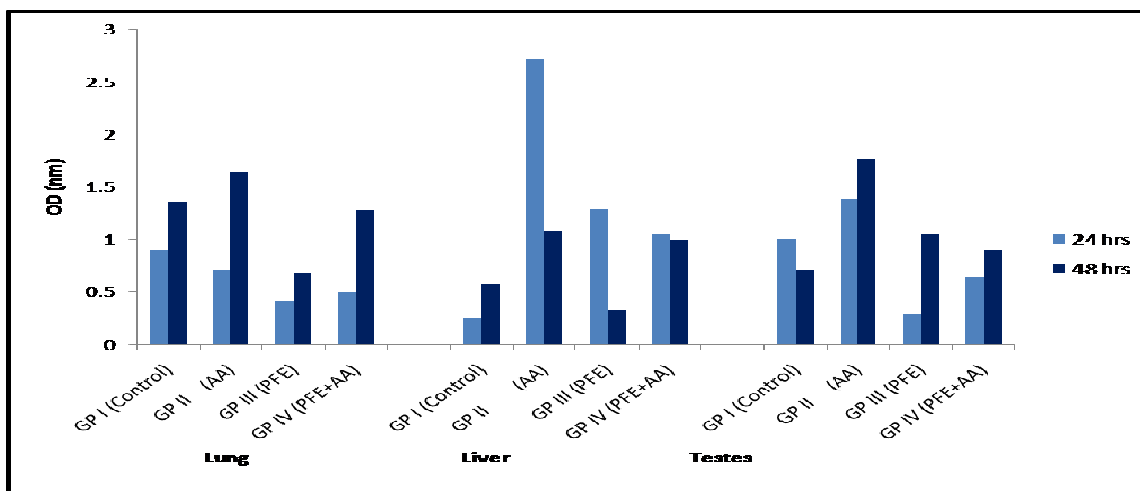


Figure 6: Variations in Cellular Proliferation of Various Biological Tissues (Lungs, Liver and Testes) in Response to Acrylamide Induction and PFE Treatment

Histology of lung showed that acrylamide clearly induced alveolar wall destruction and air space enlargement. No changes were observed in PFE treated group. There was enlargement of air spaces but to a lesser degree in Gp4 (PFE+AA) as compared to AA group (Figure. 7). Histology of liver in AA exposed group

showed increased in number of hepatocytes. In PFE treated group, vacuolization was observed and there were no significant changes in Gp 4 when compared to Gp2 but vacuolization was lesser in degree (Figure. 8).

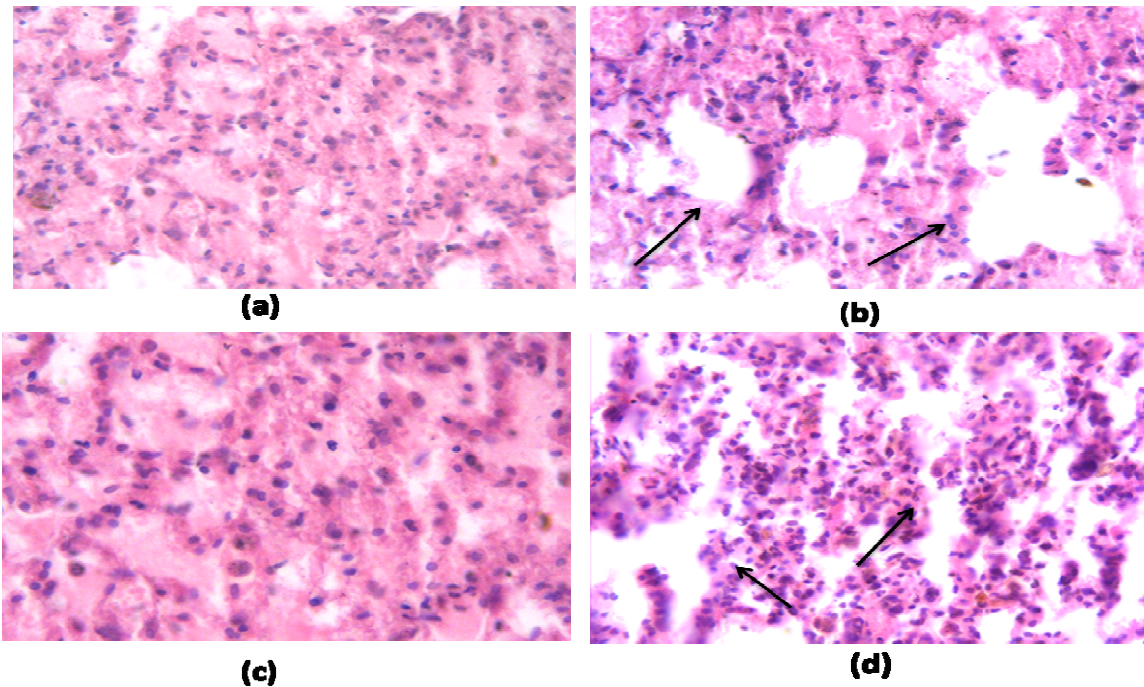


Figure 7: Histological Changes in the Pulmonary Tissues in (a) Control (b) Induction of Carcinogenesis by Acrylamide (arrows show enlargement of air space as compared to control), (c) Treatment with only PFE, (d) Treatment with PFE followed by Acrylamide Administration (lesser degree of air space enlargement as indicated by arrows) (at 40X Magnification)

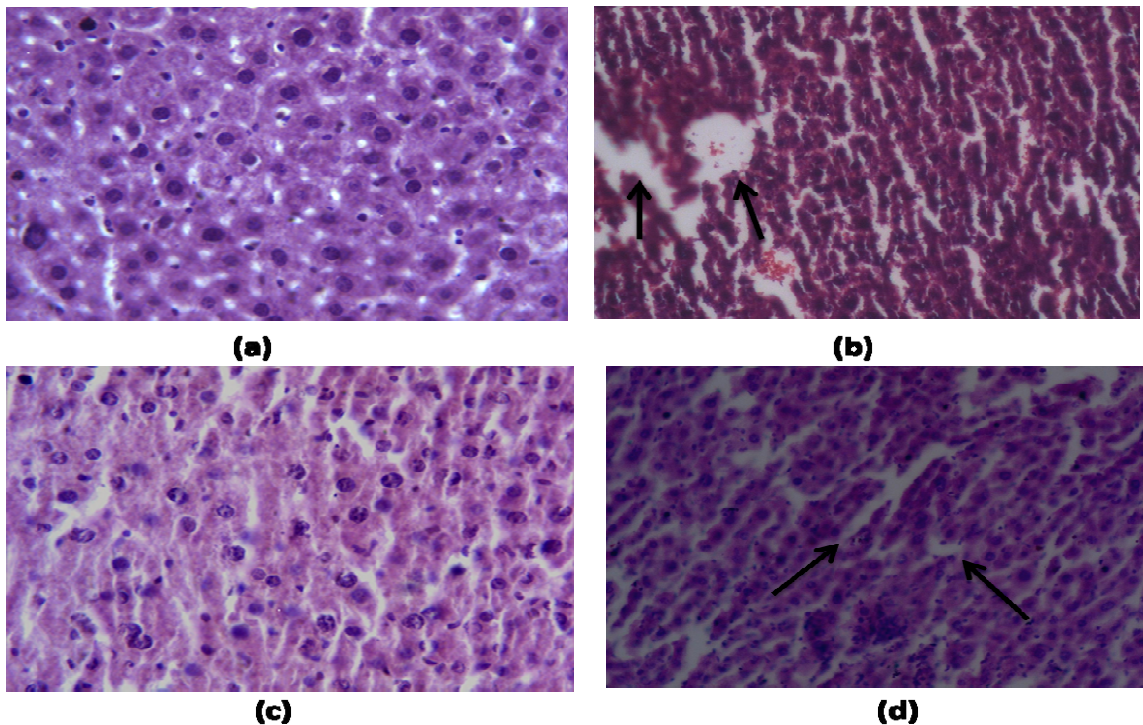


Figure 8: Histological Changes in the Hepatic Tissues (a) Control (b) Induction of Carcinogenesis by Acrylamide (arrows depict vacuolization in hepatic cells), (c) Treatment with only PFE, (d) Treatment with PFE followed by Acrylamide Administration (lesser degree of vacuolization as shown by arrows) (at 40X Magnification)



Discussion

The administration of pomegranate fruit extract to acrylamide treated mice has beneficial effects in counteracting the carcinogenic action of acrylamide by promoting the activity of carcinogen detoxification enzymes (GSH, GPx, CAT, GST, SOD) in the pulmonary, testicular and hepatic tissues.

Acrylamide is perfectly capable of increasing the tumor yield in mice. It is structurally similar to vinyl carbamate which is a proposed proximate to carcinogenic form of ethyl carbamate and thus it possesses similar carcinogenic properties.[29] GST is an important phase II carcinogenic biotransformation enzyme that catalyzes the conjugation of various endogenous and exogenous compounds with the non protein thiol, glutathione. This conjugation reaction inhibits the reactive cellular nucleophiles from reaching cellular targets such as DNA, RNA and protein and result in the production of thiol-ether linked glutathione conjugate that is less toxic and readily excreted from the body via a GSH-conjugate recognizing transporter.[30] After absorption acrylamide is also rapidly metabolized primarily by GSH conjugation.[31] GST and GSH inducers are considered to be the potential inhibitors of the acrylamide- biomolecules adduct formation.[32] The GST activity in lungs was found to be increased with the administration of acrylamide possibly due to the increased formation of conjugates between acrylamide and GSH.[33] However there was a decrease in the GST activity in all the three type of tissue of the PFE+AA treatment group, clearly showing the dilapidating effects of PFE on acrylamide. Similar results were demonstrated by Schwartz *et al.*, 1992 showing a decline in GST levels in human oral carcinoma cells under the effects of β - carotene treatment.[34]

The GPx activity in the treatment (PFE+AA) group was found to be increasing in almost hepatic and testicular cell types. Significant ($p < 0.05$) increase in the GPx activity was also reported in a wide range of tumor cells compared to control.[35] The observed increase in the GPx activity confirms that the enzyme is actively involved in protecting the cell from hydrogen peroxide. However in the pulmonary cells, the treatment (PFE+AA) group showed slight decrease in GPx activity as compared to control. The result was, however, in coherence with similar observations by Palozza *et al.* (2000), who demonstrated that Glutathione activity decreases by 35% ($p < 0.01$) in canthaxanthin treated mice.[36]

Hydrogen peroxide is the normal cellular metabolite that is produced during the oxidative damage to tissues.[37] Predominantly two systems are responsible for the decomposition of endogenously produced H_2O_2 viz. GPx and catalase (CAT). At low H_2O_2 levels, the decomposition of organic peroxides is catalyzed by CAT.[38] Under conditions of oxidative stress, cells increase the concentration of some antioxidant enzymes, most commonly MnSOD and Catalase. We report a significant decrease in the CAT activity in the AA treated group. The suppressed activity of CAT may be correlated to high activity of GPx which utilizes H_2O_2 as substrate causing a decline in generation of H_2O_2 . Evidences of weakened activity in tumor cells have been reported in numerous studies on antioxidant scavengers.[39] Helen and

Vijayammal PL (1997) reported a relation between cigarette smoke and decrease in catalase activity in several organs such as liver, lungs and heart, where they have reported a decrease in CAT activity on CS exposure.[40]

Moreover there was a significant ($p < 0.05$) increase in the pulmonary and testicular SOD activity in the AA cells as compared to the control group, which later on decreased in the PFE+AA conjunctive group. The increase in the SOD activity could be to combat the free radicals generation during the acrylamide toxicity.[41] Yousuf and El-Demerdash, 2005, also reported similar enhanced SOD activity in the acrylamide treated testicular cells.[33] Besides studies by Kirkova *et al.*, 2007, have suggested an increase in SOD activity following aspirin administration to rats.[42] Wengen *et al.* (2002) have observed an increase in hepatic tissue of Syrian hamster after treatment with celecoxib.[43] Apoptosis or programmed cell death is a major control mechanism by which a cell dies when the DNA damage is not repaired.[44] It is also pioneer in controlling the cell number and proliferation as part of normal development. The proliferation was assessed by the MTT study[28] and estimation of the total concentration which demonstrated the growth and survival of the cell. In the present study there was an increase in cell proliferation after 24 and 48 hr in acrylamide administered mice. Acrylamide have been shown to induce morphological transformations in C3H/ 10T1/ 2 and NIH/ 3T3 cells[45] as well as in BALB/ c3T3 cell lines.[46] Acrylamide binds to the cytoskeleton system and causes modification in the shape resulting in the altered growth related cellular functions[47,48] which may further be involved in the acrylamide-induced cellular transformation and carcinogenicity.

Histopathological analysis showed that the lung of mice from control group depicted normal architecture. AA exposure clearly induced alveolar wall destruction and air space enlargement, which decreased in the co treatment group. Similarly liver cells architecture of the AA treated cells were also altered showing increased number of hepatocytes and distinct occurrence of hyperchromatia. The vacuolization were however to a lesser degree in the co-treatment group. Llovet *et al.*, (2003) have also reported moderate vacuolization of hepatocytes in liver of rats exposed to tobacco smoke.[49]

Conclusion

The present study evidently show that pomegranate fruit extract administration to acrylamide treated mice has beneficial effects in counteracting its carcinogenic action since it decreases the activity of carcinogen action by promoting the activity of carcinogen detoxification enzymes (GSH, GPx, CAT, GST, SOD, etc) in pulmonary, testicular and hepatic tissues. In the light of the present work, pomegranate and other fruit extracts could well be scrutinized for their preventive as well as therapeutic roles, to reduce the incidence of cancer by checking the onset of carcinogenesis.

Abbreviations

AA- Acrylamide Administration; CAT- Catalase; PFE- Pomegranate Fruit Extract; GPx- Glutathione Peroxidase; GST- Glutathione S-Transferase; GSH- Reduced Glutathione; PBS- Phosphate Buffer Saline; SOD- Superoxide Dismutase

Authors' contributions

Jayanand participated in the design of the study and statistical analysis.

Renuka Ganger and Dr. V. K. Gupta carried out the animal experimentation, biochemical estimation and electron microscopic study.

DV Rai and Anvesha Sinha participated in coordination and drafted the manuscript.

Acknowledgement

Authors are thankful to Panjab University, Chandigarh Department of Oncology, All India Institute of Medical Sciences, New Delhi and Shobhit University, Meerut, India for providing the all possible laboratory facilities.

Conflict of interest statement

The authors declare no conflict of interests regarding the present work.

References

- [1]. Beckett WS. Epidemiology and etiology of lung cancer. *Clin Chest Med* 1993; 14: 1-15.
- [2]. László H, Zsolt T. Epidemiology of gastrointestinal and liver tumors. *Eur Rev Med Pharmacol Sci* 2010; 14: 249-258.
- [3]. Drain L. Testicular cancer in California from 1942–1969: The California Tumor Registry experience. *Oncology* 1973; 27: 45–51.
- [4]. Maffezzini M. TC Incidence Increasing: Spread the Word. *Eur Urol* 2007; 51: 596–597.
- [5]. Agrawal AK, Seth PK, Squibb RE, Tilson HA, Uphouse LL, Bondy SC. Neurotransmitter receptors in brain regions of acrylamide- treated rats: I. Effects of a single exposure to acrylamide. *Pharmacol Biochem Behav* 1981; 14: 527–31.
- [6]. Johnson KA, Gorzinski SJ, Bodner KM, Campbell RA, Wolf CH, Friedman MA, et al. Chronic toxicity and oncogenicity study on acrylamide incorporated in the drinking water of Fischer 344 rats. *Toxicol Appl Pharmacol* 1986; 85(2): 154–168.
- [7]. Bull RJ, Robinson M, Laurie RD, Stoner GD, Greisiger E, Meier JR, et al. Carcinogenic effects of acrylamide in Sencar and A/J mice. *Cancer Res* 1984; 44(1): 107–111.
- [8]. Bull RJ, Robinson M, Stober JA. Carcinogenic activity of acrylamide in the skin and lung of Swiss-ICR mice. *Cancer Lett* 1984; 24 (2): 209 – 212.
- [9]. Friedman MA, Dulak LH, Stedham MA. A lifetime oncogenicity study in rats with acrylamide. *Fundamen Appl Toxicol* 1995; 27 (1): 95–105.
- [10]. Song-Tay L, Min-Hua L, Lan-Hsiang C, Ting-Feng W, Li-Chien H, Gwo-Ing L. Suppression of urinary bladder urothelial carcinoma cell by the ethanol extract of pomegranate fruit through cell cycle arrest and apoptosis. *BMC Compl Alter Med* 2013; 13: 364.
- [11]. Cerda B, Ceron JJ, Tomas-Barberan FA, Espin JC: Repeated oral administration of high doses of pomegranate ellagitannin punicalagin to rats for 37 days is not toxic. *J Agri Food Chem* 2003; 51: 3493–3501.
- [12]. Cerda B, Llorach R, Ceron JJ, Espin JC, Tomas-Barberan FA: Evaluation of the bioavailability and metabolism in the rat of punicalagin, an antioxidant polyphenol from pomegranate juice. *Eur J Nutr* 2003; 42: 18–28.
- [13]. Gil MI, Tomas-Barberan FA, Hess-Pierce B, Holcroft DM, Kader AA: Antioxidant activity of pomegranate juice and its relationship with phenolic composition and processing. *J Agri Food Chem* 2000; 48: 4581–4589.
- [14]. Hong MY, Seeram NP, Heber D: Pomegranate polyphenols downregulate expression of androgen synthesizing genes in human prostate cancer cells overexpressing the androgen receptor. *J Nutr Biochem* 2008; 19: 848–855.
- [15]. Aviram M, Dornfeld L, Kaplan M, Coleman R, Gaitini D, Nitecki S et al. Pomegranate juice flavonoids inhibit low-density lipoprotein oxidation and cardiovascular diseases: studies in atherosclerotic mice and in humans. *Drugs Exp Clin Res* 2002; 28(2-3): 49-62.
- [16]. Lippman SM, Lee JJ, Sabichi AL. Cancer chemoprevention: progress and promise. *J Nat Cancer Inst* 1998; 90: 1514–1528.
- [17]. Afaq F, Saleem M, Krueger CG, Reed JD, Mukhtar H. Anthocyanins- and hydrolysable tannin-rich pomegranate

- fruit extract modulates MAPK and NF- κ B pathway and inhibits skin tumorigenesis in CD-1 mice. *Int J Cancer* 2005; 113: 423–433.
- [18]. Kawaii S, Lansky EP. Differentiation-promoting activity of pomegranate (*Punica granatum*) fruit extracts in HL-60 human promyelocytic leukemia cells. *J Med Food* 2004; 7: 13–18.
- [19]. Khan N, Adhami VM, Mukhtar H. Apoptosis by dietary agents for prevention and treatment of prostate cancer. *Endocr Relat Cancer* 2010; 17(1): R39–R52.
- [20]. Adams LS, Seeram NP, Agarwal BB, Takada Y, Sand D, Heber D. Pomegranate juice, total pomegranate ellagitannins and punicalagin suppress inflammatory cell signalling in colon cancer cells. *J Agri Food Chem* 2006; 54: 980-985.
- [21]. Ashwell JD. The many paths to p38 mitogen-activated protein kinase activation in the immune system. *Nat Rev Immunol* 2006; 6: 532–40.
- [22]. Luck H. Catalase In: *Methods of Enzymatic Assays* (Ed): HU Bergmeyer. New York, Academic Press. 1965; 885-894.
- [23]. Kono Y, Fridovich I. Superoxide radicals inhibit catalase. *J Biol Chem* 1982; 257: 5751-5754.
- [24]. Moron MS, Depierre JW, Mannervik B. Levels of glutathione, glutathione reductase and glutathione S-transferase activities in rat lung and liver. *Biochim Biophys Acta* 1979; 582: 67–78.
- [25]. Paglia DE, and Valentine WN. Studies on the quantitative and qualitative characterization of glutathion peroxidase. *J Lab Med* 1987; 70: 158-165.
- [26]. Habig WH, Jakoby WB. Assays for differentiation of glutathione S-transferases. *Methods Enzymol* 1981; 77: 398–405.
- [27]. Lowry O, Rosebrough A, Far A, Randall R. Protein measurement with folin phenol reagent. *J Biol Chem* 1951; 193: 680-685.
- [28]. Supine R. MTT assay. In the ERGATT/FRAME Data Bank. *In vitro Techniques in Toxicology* 1990; 17.
- [29]. Dahl GA, Miller JA, Miller EC (1978). Vinyl carbamate as a promutagen and a more carcinogenic analog of ethyl carbamate. *Cancer Res* 1978; 38: 3793- 3804.
- [30]. Nakamura Y, Ohigashi H, Masuda S et al. (2000). Redox regulation of glutathione-S-transferase induction by benzyl isothiocyanate: correlation of enzyme induction with the formation of reactive oxygen intermediates. *Cancer Res* 2000; 60: 219-225.
- [31]. Sumner SC, Williams CC, Snyder RW, Krol WL, Asgharian B, Fennell TR. Acrylamide: a comparison of metabolism and haemoglobin adducts in rodents following dermal, intraperitoneal, oral or inhalation exposure. *Toxicol Sci* 2003; 75: 260-70.
- [32]. Qunying X, Ye L, Hongfang S. Inhibition of acrylamide toxicity in mice by three dietary constituents. *J Agri Food Chem* 2008; 56: 6054-6060.
- [33]. Yousuf MI and El-Demerdash. Acrylamide induced oxidative stress and biochemical perturbations in rats. *Toxicol* 2006; 219: 133-141.
- [34]. Schwartz JL, Tanaka J, Khandekar V, Herman TS, Teicher B. β -Carotene and/or vitamin E as modulators of alkylating agents in SCC-25 human squamous carcinoma cells. *Chemother Clin Pharm* 1992; 50: 367-373.
- [35]. Balasenthil S, Nagini S, Arivazhagan S. Reactive oxygen species oxidative damage and pathogenesis. *Current Sci* 1999; 77(5): 658-65.
- [36]. Palozza P, Calviello G, De Leo ME, Serini S, Bartoli GM. Canthaxanthin supplementation alters antioxidant enzymes and iron concentration in liver of Balb/c mice. *J Nutri* 2000; 130: 1303-1308.
- [37]. Chance B, Sies H, Boveris A. Hydrogen peroxide mechanism in mammalian organs. *Physiol Rev* 1979; 59: 527-605.
- [38]. Yu BP. Cellular defences against damages from reactive oxygen species. *Am Physiol Soc* 1994; 139-62.
- [39]. Oberley LW, Oberley TD. Free radicals and aging. In free radicals, ageing and degenerative diseases. Johnson JE, Walford R Jr., Harmon D, Maguel J, editors. New York Liss 1986; 325-71.
- [40]. Helen A, Vijayammal PL. Effects of Vitamin A supplementation on cigarette smoke induced lipid peroxidation. *Vet Hum Toxicol* 1997; 39(1): 18-21.
- [41]. Sridevi B, Reddy KV, Reddy SLN. Effect of trivalent and hexavalent chromium on antioxidant enzyme activities and lipid peroxidation in a freshwater field crab. *Barytellphusa guerini*. *Bull Environ Contam Toxicol* 1998; 61 : 384-390.
- [42]. Kirkova M, Alexandro A, KEsiova M, Todorov S. In vivo effects of amtolmetin guacyl on lipid peroxidation and antioxidant defence systems. Comparisons with non-selective and COX-2 selective NSAIDS. *Auton Autocoid Pharmacol* 2007; 27(2): 99-104.
- [43]. Wengen FA, Killian M, Bisevac M, Khodadayan C, von Seebach M, Schimke I et al. Effects of Colecoxib and Zylfo on liver metastasis and lipid peroxidation in pancreatic cancer in Syrian hamsters. *Clin Exp Metastasis* 2002; 19: 681-687.
- [44]. Lowe SW, Lin AW. Apoptosis in cancer. *Carcinogenesis* 2000; 21: 485-495.
- [45]. Banerjee S, Segal A. In vitro transformation of C3H/ 10T1/ 2 and NIH/ 3T3 cells by acrylonitrile and acrylamide. *Cancer Lett* 1986; 32: 698-701.
- [46]. Tsuda HS, Taketomi CS, Hasegawa MM, Hamada A, Katawa KM, Inui N. Acrylamide: induction of DNA damage and chromosomal aberrations and cell

- transformation without gene mutations. *Mutagenesis* 1993; 8: 23-29.
- [47]. Liaw L, Schwartz SM. Microtubule disruption stimulates DNA synthesis in bovine endothelial cells and potentiates cellular response to basic fibroblast growth factor. *Am J Pathol* 1993; 143: 937-948.
- [48]. Pienta KJ, Coffey DS. Nuclear-cytoskeletal interaction: evidence for physical connections between nucleus and cell periphery and their alteration by transformation. *J Cell Biochem* 1992; 49: 357-365.
- [49]. Llovet JM, Burroughs A, Bruix J. Hepatocellular carcinoma. *Lancet* 2003; 362: 1907-1917.

