

Hepatoprotective Activity of *Chenopodium Album* Linn. Against Alcohol Induced Liver Damage

Vijay Nigam¹, Padmaa M Paarakh^{2*}

*Corresponding author:

Dr. Padmaa M Paarakh

¹Department of Pharmacognosy,
SRET College of Pharmacy, P.O.
Tipper, Distt: Hamirpur (H.P.)

²Department of Pharmacognosy
The Oxford College of Pharmacy
6/9, I Cross, Begur Road
Hongasandra,
Bangalore 560068

ABSTRACT

Dried aerial parts of *Chenopodium album* Linn. (Chenopodiaceae) are used in variety of diseases in traditional Indian system of medicine including hepatic ailments. The aim of present study was to validate hepatoprotective activity of aerial parts of *Chenopodium album* Linn using alcohol as chronic hepatitis model. Alcoholic [ALCA] and aqueous [AQCA] extracts of the aerial parts of *Chenopodium album* at the doses of 200 and 400 mg/Kg were evaluated for hepatoprotective activity against alcohol induced hepatotoxicity using biochemical markers and by histopathological method. The aqueous extract at a dose of 400 mg/kg was found to be more potent when compared to Silymarin. ALCA and AQCA [200 & 400 mg/Kg] showed significant hepatoprotective activity against alcohol induced hepatotoxicity as evident by restoration of serum transaminases, alkaline phosphatase and bilirubin content. Histopathology of the liver tissue further confirmed the reversal of damage induced by hepatotoxin. Present study showed that the alcoholic and aqueous extracts of *Chenopodium album* significantly restore physiological integrity of hepatocytes. Aqueous and alcoholic extract did not show any sign of toxicity up to oral dose of 5 g/Kg in mice.

Keywords: *Chenopodium album* Linn; hepatoprotective activity; alcohol; chronic hepatitis model; serum biochemical assessment; histopathology.

Introduction

Liver diseases have become a global concern worldwide. The principal causative factor is increasing alcohol consumption, infection, malnutrition, anemia and availability of hepatotoxic drugs over the counter. Treatment options for common liver diseases such as cirrheses, fatty liver and chronic hepatitis are problematic. The conventional drugs used in the treatment of liver diseases viz., corticosteroids, antiviral and immunosuppressant agents are sometimes inadequate and may lead to serious adverse effects. Paradoxically, these may themselves cause hepatic damage. Eg: cholestatic jaundice with

azathioprine and elevation of serum transaminases by interferon and virazole [1]. It is therefore imperative to search alternative drugs for the treatment of liver disease to replace the currently used drugs of doubtful efficacy and safety [2]. In absence of a reliable liver protective drug in the modern system of medicine, a number of medicinal preparations in Ayurveda, the Indian system of medicine, are recommended for the treatment of liver disorders. Natural remedies from medicinal plants are considered to be effective and safe alternative treatments for hepatotoxicity.



In such context, one such drug is *Chenopodium album* Linn which has ethno pharmacological relevance to be used for hepatic disorders [3]. *Chenopodium album* Linn (*Chenopodiaceae*) found wild up to an altitude of 4700 m and cultivated throughout India particularly Western Rajasthan, Kulu valley and Shimla. It is commonly known as Lamb's quarte, wild spinach, white goosefoot in English [4, 5]. In Tradition System of Medicine, it is used as an anthelmintic, antidiarrhoeal, antiphlogistic, antirheumatic, contraceptive, odontalgic, laxative, cardiotoxic, antiscorbutic, blood purifier, hepatic disorder, spleen enlargement, biliousness, intestinal ulcers, digestive, carminative, aphrodisiac, dyspepsia, flatulence, strangury, seminal weakness, pharyngopathy, splenopathy, hemorrhoids, ophthalmopathy, cardiac disorder and general debility [6-9]. The phytoconstituents isolated so far from the plant are ascorbic acid, β -carotene, catechin, gallic acid, caffeic acid, p-coumaric acid, ferulic acid, β -sitosterol, campesterol, xanthotoxin, stigmasterol, n-triacontanol, imperatorin, ecdysteroid [10], cinnamic acid amide alkaloid [11], phenol, saponin, apocartenoids [12], cryptomeridiol [13], n-trans-feruloyl-4-O-methyl dopamine and syringaresinol [14] and β -sitosterol, lupeol and 3 hydroxy nonadecyl henicanoate [15]. The pharmacological activity reported so far from this plant are antipruritic, antinociceptive activity [16], anthelmintic activity [17], as vaginal contraceptive [18], antibacterial activity [19], antiulcer activity [20] and hepatoprotective against paracetamol induced hepatotoxicity [21].

As there is not report on hepatoprotective activity, this prompted us to investigate the hepatoprotective activity of aerial parts of *Chenopodium album* extracts.

Materials and Methods

Plant Material

Plant material used in the study consisted of aerial parts of *Chenopodium album* Linn, collected from the local area of Nadaun, Distt. Hamirpur (H.P.), and authenticated by Dr. Sushil Vashi, Reader, Department of Botany, Govt Degree College of Arts, Commerce and Science, Hamirpur (H.P.). A voucher specimen is preserved in the Department.

Preparation of plant extract:

Crude aerial parts of *Chenopodium album* were subjected to pulverizations and passed through sieve no. 40. The powder [300 g] was packed into a soxhlet apparatus and extracted with petroleum ether (60-80°C) for 18 h. The same marc was successively extracted with alcohol and afterwards with distilled water for 18 hours. Each time the marc was dried and later extracted with other solvents. All the extract were concentrated by rotary vacuum evaporator and evaporated to dryness and the percentage yield was found to be 2.3, 0.6 and 15.3 % w/w respectively.

Chemicals

Silymarin (Sigma Chemicals, USA) and alcohol (CDH, Mumbai) were purchased. Other chemicals and reagents used for extraction were of AR grade. Biochemical kits like AST, ALT, ALP, albumin, total protein, direct bilirubin and total bilirubin were obtained from Span Diagnostics Ltd. Surat, India.

Experimental Animal

Wistar albino rats (150-200g) were maintained in the animal house of Despanday labs, M.P.

Nagar, Bhopal (M.P.) for experimental purpose. Then all the animals were acclimatized for

seven days under standard husbandry conditions, i.e. room temperature of $25 \pm 1^{\circ}$ C; relative

humidity 45-55% and a 12:12h light/ dark cycle. The animals had free access to standard rat

pellet, with water supplied ad libitum under strict hygienic conditions. Animals were habituated to laboratory conditions for 48 hours prior to experimental protocol. All the protocols and the experiments were conducted in strict compliance according to ethical principles and guidelines provided by Committee for the Purpose of Control and Supervision of Experiments on Animals (CPCSEA).

Experimental Study

Determinations of Acute Oral Toxicity (LD₅₀)

The acute oral toxicity (AOT) of alcoholic and aqueous extract of aerial parts of *Chenopodium album* were determined by using female albino rats (Wistar strains)

weighing between 180-220 g. The animals were fasted 3 hrs prior to the experiment, up and down procedure (OECD Guideline no. 425). Animals were administered with single dose of extracts dissolved in 2% w/v acacia and observed for its mortality during 48 hours study period (short term) toxicity. Based on short-term profile of drug, the dose of the next animals was determined as per as OECD guideline 425. All the animals were also observed for long term toxicity (14 Days). The LD₅₀ of the test extract was calculated using AOT 425 software provided by Environmental protection agency, USA.

Evaluation of Hepatoprotective Activity

The alcoholic and aqueous extracts were evaluated for their hepatoprotective activity using alcohol induced chronic hepatic injury [22]. Wistar rats, weighing (180-220 g) were divided into 7 groups consisting of 6 animals in each group.

Group 1: Normal group: animal of this group receive distilled water p.o. for 30 days.

Group 2: Control group: animal of this group received vehicle and alcohol 3ml/ 100g/day p.o. for 30 days.

Group 3: Standard group: animal of this group receive Silymarin 50 mg/ Kg/day p.o. and alcohol 3 ml/ 100 g/day p.o. for 30 days.

Group 4: Test group: animal of this group receive alcoholic extract of aerial parts of *Chenopodium album* 200 mg/Kg/day and alcohol 3 ml/ 100 g/day p.o. for 30 days.

Group 5: Test group: animal of this group receive alcoholic extract of aerial parts of *Chenopodium album* 400 mg/Kg/day and alcohol 3 ml/100 g/day p.o. for 30 days.

Group 6: Test group: animal of this group receive aqueous extract of aerial parts of *Chenopodium album* 200 mg/Kg/day and alcohol 3 ml/100 g/day p.o. for 30 days.

Group 7: Test group: animal of this group receive aqueous extract of aerial parts of *Chenopodium album* 400 mg/Kg/day and alcohol 3 ml/100 g/day p.o. for 30 days

Alcohol (28.5%) was given 3 ml/100 g/day in two divided doses after one hour of drugs treatment of Group 2, 3, 4, 5, 6, and 7 for 30 days.

Blood samples were collected and serum was used for estimation of Aspartate aminotransferase [AST], Alanine aminotransferase [ALT], alkaline phosphatase [ALP], albumin [ALB], total protein [TLP], total bilirubin [TBIL] and direct bilirubin [DBIL]. The liver was washed by normal saline, blotted with filter paper and weighed immediately (Mastuda et al., 1991).

Histopathological studies:

Liver was sliced and pieces were preserved in 10% formalin for proper fixation. These tissues were processed and embedded in paraffin wax. Section of 5- 6 microns in thickness were cut and stained with hematoxylin and eosin. All the sections of the tissues were examined under microscope for analyzing the altered architecture due to the liver tissue due to paracetamol challenge and improved liver architecture due to pretreatment with test extracts and standard drug [23] which was documented by photograph.

Statistical analysis

Results were expressed as mean \pm SEM. Statistical analysis was carried out using one-way ANOVA followed by Tukey Kramer's Post Hoc Test.

Results

Acute Oral Toxicity Study:

Different doses of alcoholic and aqueous extracts were screened for their oral toxicity. No mortality was recorded till 5000 mg/Kg with alcoholic and aqueous extracts, hence the extracts were found to be safe up to the dose levels of 5000 mg/Kg.

Alcohol induced acute hepatic injury:

Liver weight and volume:

Administration of alcohol has produced a significant increase in wet liver weight and volume. Rats pretreated with Silymarin (50 mg/Kg, p.o.), AQCA (400

mg/Kg, p.o.) and ALCA (400 mg/Kg, p.o.) showed significant decrease in liver weight and volume compared to the toxic control group [Table 1 and Fig 1].

Serum Biochemical parameter:

Alcohol (3 ml/100 g/p.o.; b.i.d.) administration resulted in significant elevated the biochemical parameters like AST, ALT, ALP, direct bilirubin and total bilirubin levels, while albumin and total protein were found to be decreased compared to normal group. Pretreatment with Silymarin, AQCA and ALCA significantly prevented the biochemical changes induced by paracetamol. The hepatoprotective effect offered by AQCA (400 mg/Kg, p.o.) was found to be significantly greater than ALCA (400 mg/Kg, p.o.) and standard (Silymarin 50 mg/Kg, p.o.) group. [Table 2 and Fig 2, 3, 4]

Histology

In normal animals, liver sections showed normal hepatic cells with well preserved cytoplasm, prominent nucleolus and central vein (Fig 5 A).

In alcohol (3 ml/ 100g, p.o. for 30 days) treated animals the sections shows sever degree of liver damage, showing congestion, macrovesicular and microvesicular steatosis (Fig 5B).

In AQCA (400 mg/Kg, p.o.) treated animals, liver section showing mild inflammation and congestion, overall picture resembles normal liver (Fig 5C).

In ALCA (400 mg/Kg, p.o.) treated animals, the liver sections showing moderate inflammation and congestion (Fig 5D).

In Silymarin (50 mg/Kg, p.o.) treated animals, the liver sections showing inflammation in the periportal region and moderate congestion (Fig 5E).

Discussion

The liver can be injured by many chemicals and drugs. In the present study, alcohol was selected as a hepatotoxicant to induced liver damage. The primary objective of this study is to assess the hepatoprotective

activity of *Chenopodium album* against chronic liver damage.

In the case of alcoholic liver disease (ALD), no such comprehensive animal model currently exists. Researchers have not been able to develop this model for reasons that are not understood as yet, but which probably involve genetic differences between humans and other animals [24].

In the absence of a comprehensive model, ALD studies using animals are designed to answer specific questions about different aspects of the disease, usually addressing only one or two experimental variables at a time while holding others constant. Consequently, it was through interesting to standardize a model using alcohol as hepatotoxic agent and to screen various indigenous drugs for their hepatoprotective action [22, 24]. Ethanol, even after short-term consumption, induced CYP2E1 enzyme activity in doses that do not causes fatty changes. This enzyme accelerates alcohol metabolism with a resultant increase in acetaldehyde productions [25]. Acetaldehyde is thought to have number of adverse effects like decreased transport and secretion of proteins owing to tubulin polymerization, enhanced vitamin metabolisms and traces metals, which lead to fatal liver disorder [26, 27, 28].

The hepatotoxic dose (3 ml/100 g/b.i.d. for 30 days) of alcohol produced an elevation in the liver weight & volume and serum AST, ALT, ALP, direct and total bilirubin, while albumin and total protein were found to be decreased compared to normal group. In experimental animals pretreated with *Chenopodium album* linn. extracts (AQCA & ALCA) and silymarin, the total liver weight & volumes, AST, ALT, ALP, direct and total bilirubin levels were significantly lowered, while albumin and total protein significantly increased. Histopathological changes such as sever congestion, macro vesicular and microvesicular steatosis (fatty changes in hepatocytes) were observed in alcohol treated (toxic) groups. Both extracts prevented these histopathological changes, further indicating their hepatoprotective activity.

Table 1: Effect of Silymarin, AQCA and ALCA on total liver weight and volume in Alcohol induced liver damage in rats.

SNo.	Treatment	Mean liver weight (g/100g)	Mean liver volume (ml/100g)
1.	Distilled Water	3.15 ± 0.07	3.39 ± 0.08
2	2 % w/v acacia + Alcohol 3 ml/100 g, p.o.	5.686 ± 0.23	6.09 ± 0.21
3	Silymarin (50 mg/ Kg, p.o.) + Alcohol (3 ml/100 g/bid, p.o.)	3.47 ± 0.49 ^{***}	3.64 ± 0.06 ^{***}
4	AQCA (200 mg/Kg, p.o.) + Alcohol (3 ml/100 g/bid, p.o.)	4.57 ± 0.10 ^{***}	4.8 ± 0.10 ^{***}
5	AQCA (400 mg/Kg, p.o.) + Alcohol (3 ml/100 g/bid, p.o.)	3.35 ± 0.04 ^{***}	3.46 ± 0.04 ^{***}
6	ALCA (200 mg/Kg,p.o.) + Alcohol (3 ml/100 g/bid, p.o.)	4.96 ± 0.07 ^{**}	5.36 ± 0.14 ^{**}
7	ALCA (400 mg/ Kg,p.o.) + Alcohol (3 ml/100 g/bid, p.o.)	3.62 ± 0.11 ^{***}	3.74 ± 0.08 ^{***}

Values are expressed as mean ± S.E.M; n = 6.

** $P < 0.01$, *** $P < 0.001$ vs. control (Toxic), using one-way ANOVA followed by Tukey Kramer's Post Hoc test.
ALCA (alcoholic extract of *Chenopodium album*), AQCA (aqueous extract of *Chenopodium album*)

Table 2: Effect of Silymarin, AQCA and ALCA on different biochemical parameters in alcohol induced hepatotoxicity in rats.

SNo.	Treatment	Serum biochemical parameters						
		AST IU/L	ALT IU/L	ALP IU/L	ALB g/dL	TLP g/dL	BILT mg/dL	BILD mg/dL
1.	Distilled Water	89.33 ± 2.00	38.32 ± 1.04	102.73 ± 4.61	4.83 ± 0.07	14.13 ± 0.28	0.16 ± 0.01	0.32 ± 0.01
2.	2 % w/v acacia + Alcohol 3 ml/100 g, p.o.	373.14 ± 15.47	208.83 ± 4.50	329.14 ± 7.83	2.09 ± 0.07	7.55 ± 0.23	1.15 ± 0.03	1.91 ± 0.05
3.	Silymarin (50 mg/Kg, p.o.) + Alcohol (3 ml/100 g/bid, p.o.)	136.94 ± 4.40***	61.88 ± 3.25***	148.18 ± 4.16***	4.19 ± 0.12***	12.12 ± 0.16***	0.35 ± 0.02***	0.60 ± 0.01***
4.	AQCA (200 mg/Kg, p.o.) + Alcohol (3 ml/100 g/bid, p.o.)	196.38 ± 6.62***	112.62 ± 4.01***	191.6 ± 5.19***	3.2 ± 0.13***	9.15 ± 0.23**	0.79 ± 0.04***	1.15 ± 0.07***
5.	AQCA (400 mg/Kg, p.o.) + Alcohol (3 ml/100 g/bid, p.o.)	131.95 ± 2.75***	52.46 ± 2.25***	143.76 ± 2.98***	4.258 ± 0.11***	12.42 ± 0.16***	0.36 ± 0.019***	0.59 ± 0.02***
6.	ALCA (200 mg/Kg, p.o.) + Alcohol (3 ml/100 g/bid, p.o.)	227.69 ± 3.49***	146.74 ± 4.13***	300.36 ± 6.28**	2.4483 ± 0.099	8.28 ± 0.32	0.97 ± 0.03***	1.51 ± 0.06***
7.	ALCA (400 mg/Kg, p.o.) + Alcohol (3 ml/100 g/bid, p.o.)	161.42 ± 5.47***	85.11 ± 5.02***	181.47 ± 3.66***	3.4 ± 0.16***	10.27 ± 0.33***	0.73 ± 0.43***	0.97 ± 0.02***

Values are expressed as mean ± S.E. M; n = 6.

*** $P < 0.001$ vs. control (Toxic), using one-way ANOVA followed by Tukey Kramer's Post Hoc test.

ALCA (Alcoholic extract of *Chenopodium album*); AQCA (Aqueous extract of *Chenopodium album*). AST (aspartate aminotransferase), ALT (alanine aminotransferase), ALP (alkaline phosphatase), ALB (albumin), TLP (total protein), DBIL (direct bilirubin), TBIL (total bilirubin).

Fig 1: Effect of silymarin, AQCA and ALCA on liver weight and wet liver volume in alcohol induced liver damage in rats.

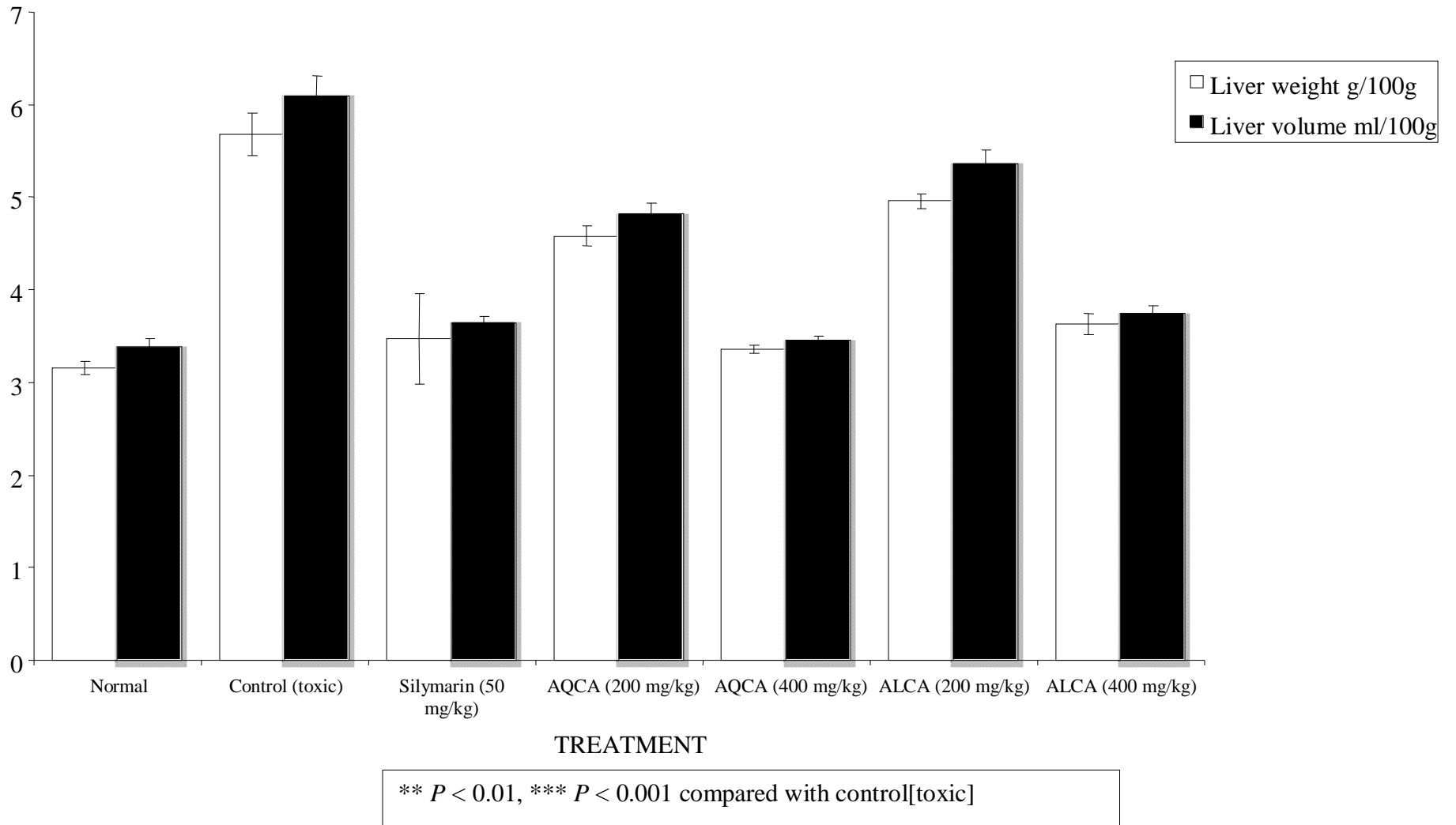
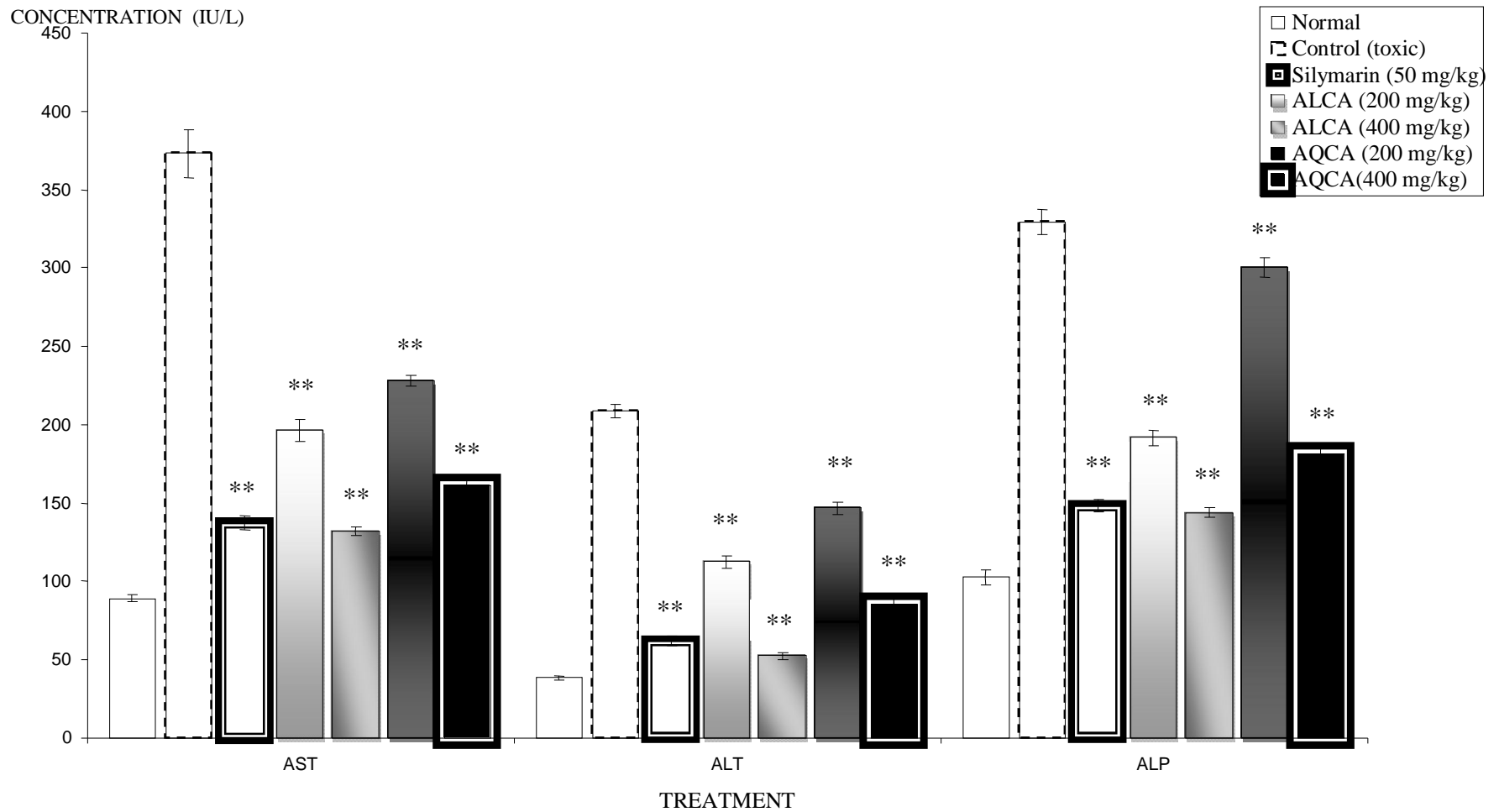
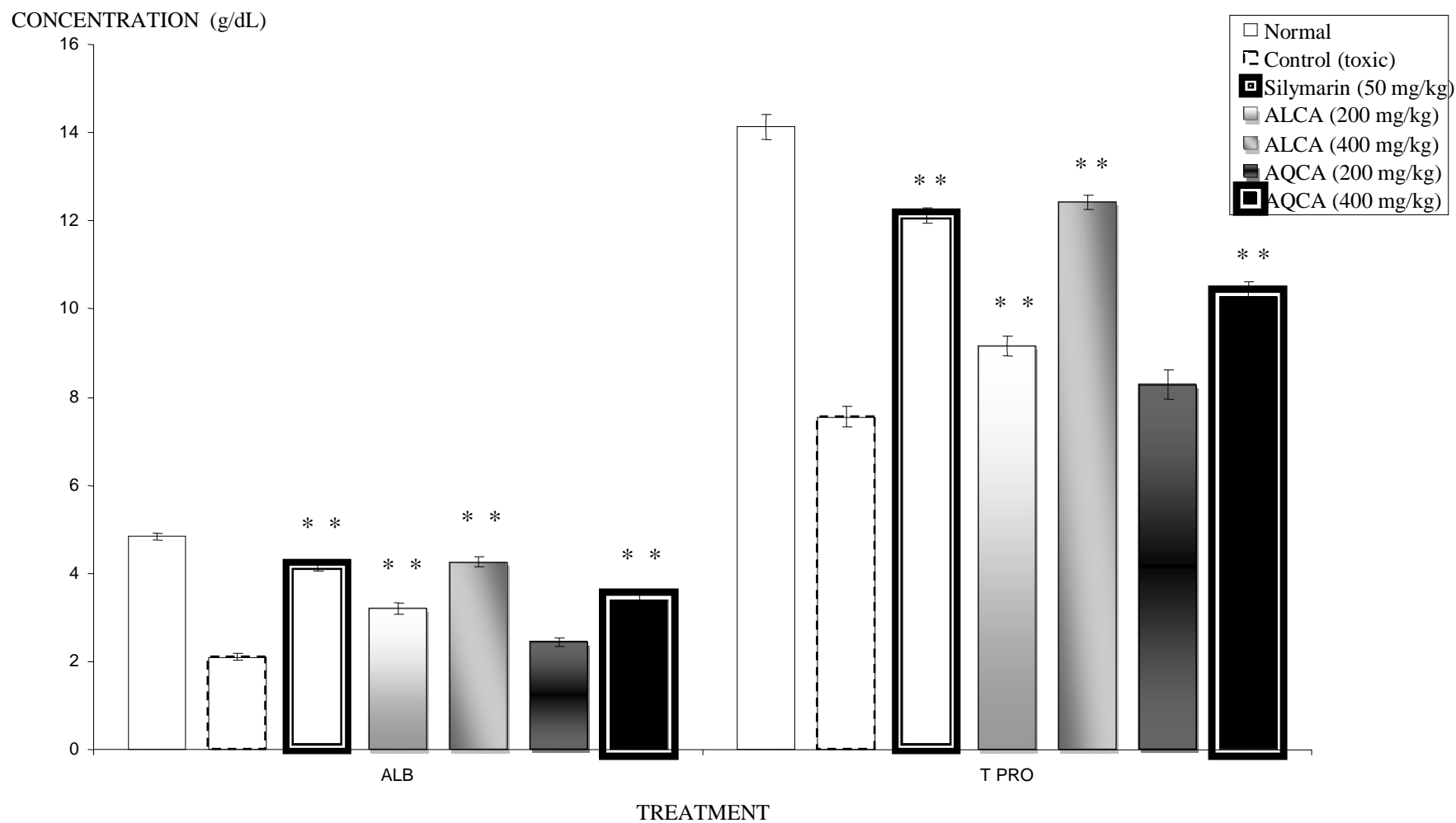


Fig 2: Effect of Silymarin, AQCA and ALCA on serum AST, ALT and ALP levels in alcohol induced liver damage in rat.



** $P < 0.001$ compared with control[toxic]

Fig 3: Effect of silymarin, AQCA and ALCA on serum albumin and total protein levels in alcohol induced liver damage in rats.



** $P < 0.001$ compared with control [toxic]

Fig 4: Effect of silymarin, AQCA and ALCA on serum direct bilirubin and total bilirubin levels in alcohol induced liver damage in rats.

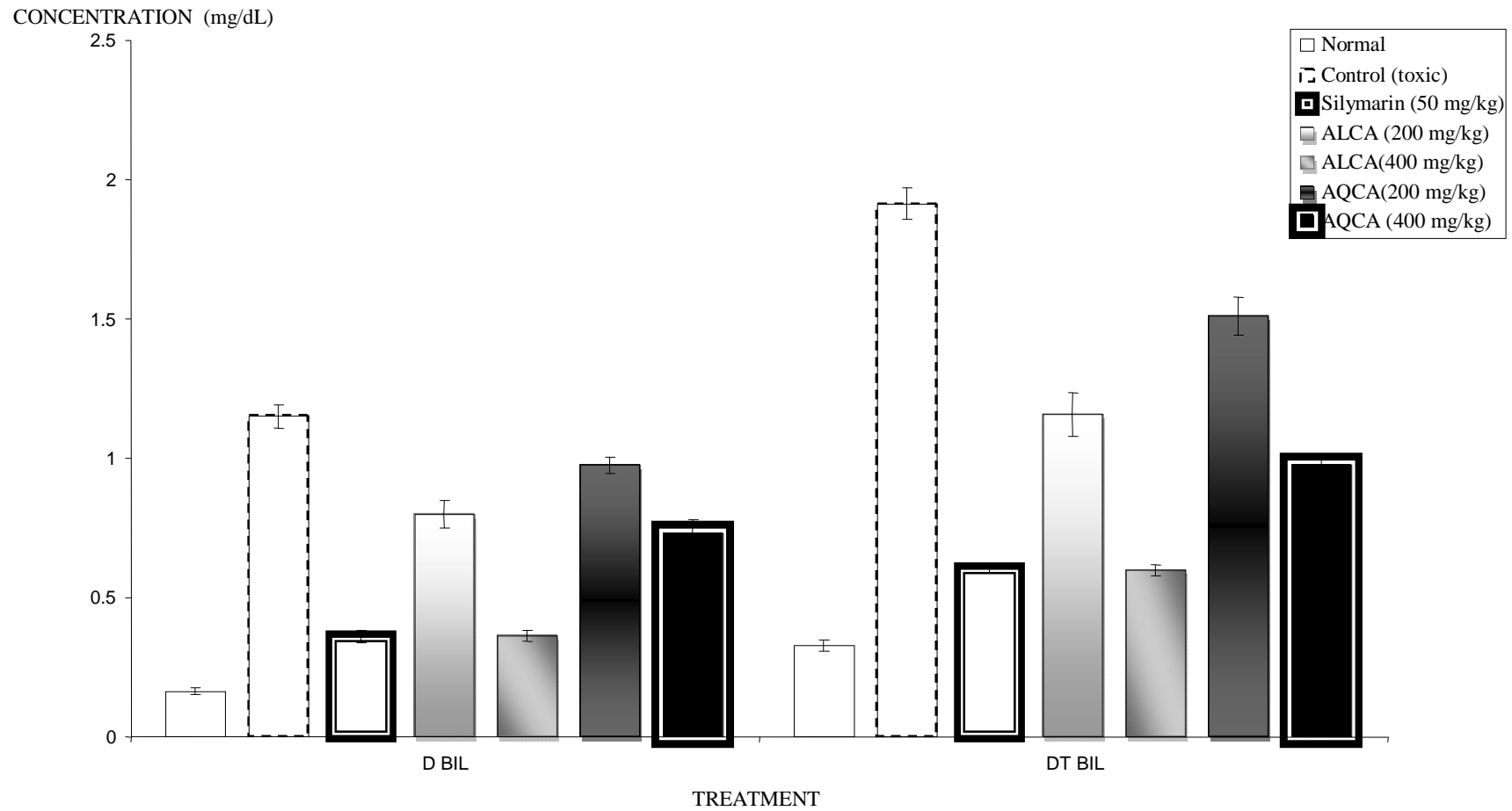


Fig 5: Sections stained with hematoxylin and eosin (400 X) displaying the liver sections of rats treated with normal, control (toxic), AQCA, ALCA and silymarin in alcohol induced liver damage in rats.

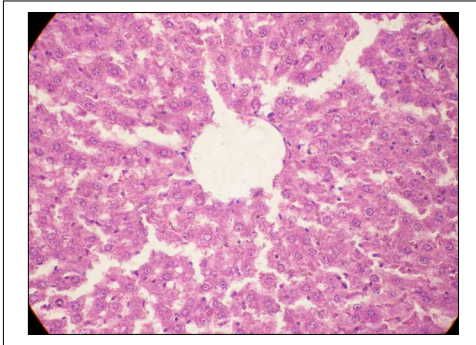


Fig: 5 [A] Normal histology of liver

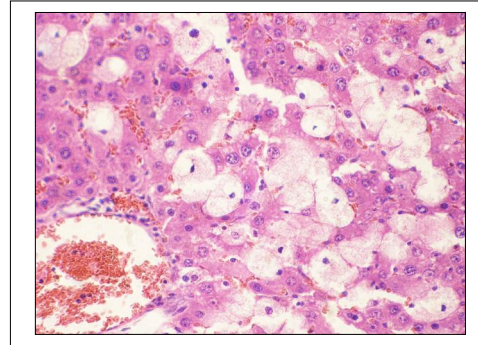
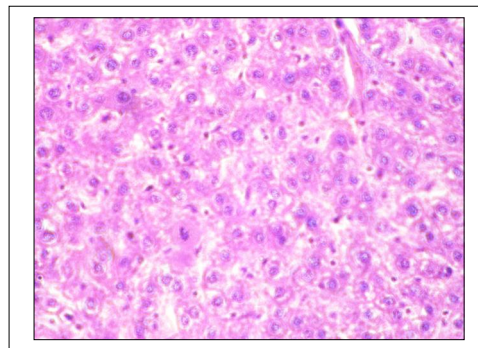


Fig: 5 [B] Control (toxic) group



5 [C] AQCA (400 mg/ kg,p.o.)

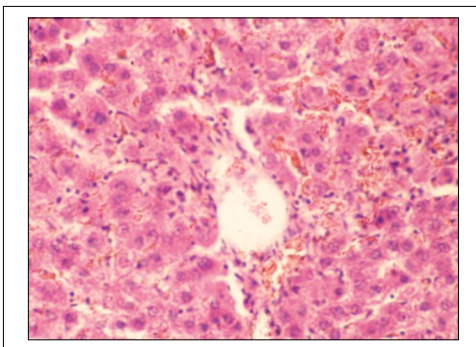


Fig: 5 [D] ALCA (400mg/kg,p.o.)

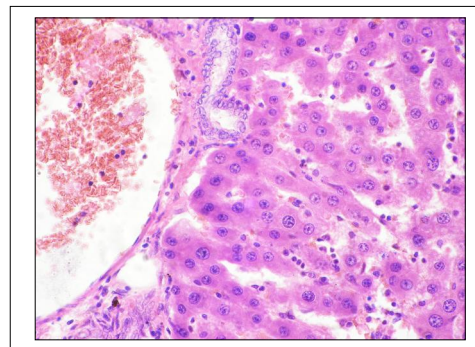


Fig: 5 [E] Silymarin (50mg/kg,p.o.)

Thus result of present study clearly demonstrate that the various biochemical (serum AST, ALT, ALP, albumin, total protein, direct bilirubin and total protein levels), physical (liver weight & volume) and histopathological alterations produced by Paracetamol in the serum and tissue were reserved significantly by the pretreatment with extracts of *Chenopodium album* and in standard group.

From the results, the hepatoprotective activity of the extracts were in the order of AQCA (400 mg/ Kg, p.o.) > Silymarin (50 mg/Kg, p.o.) > ALCA (400 mg/Kg, p.o.) > AQCA (200 mg/Kg, p.o.) > ALCA (200 mg/Kg, p.o.). Phytoconstituents like phenolic compounds and tannins were reported for their hepatoprotective and antioxidant effect [29, 30] and these two were present in alcoholic and aqueous extracts. These active principles may be accounted for hepatoprotective effect.

Conclusion

The result of present study clearly demonstrate that the various biochemical, (serum AST, ALT, ALP, albumin, total protein, direct bilirubin and total protein levels), physical (liver weight & volume) and histopathological alterations produced by paracetamol in the serum and tissue were reserved significantly by the pretreatment of extracts of *Chenopodium album* and Silymarin. This study confirms its use as hepatoprotective as per the ethno pharmacological claims.

Conflict of interest

No Conflict of interest declared.

Financial support

None

Acknowledgement

The authors are grateful to Chairman and Executive Director, Children's Education Society, Bangalore, Karnataka for providing the assistance.

Reference

1. Petri WA. Antimicrobial agents. In: Gilman AG, Hardman JG, Limbird LE, Editor. *The Pharmacological Basis of Therapeutics*. Tenth ed. New York: McGraw-Hill publication Corporation; 2001;p.1189-1193.
2. Nadeem M, Dandia PC, Pasha KV, Imran M, Balani DK, Vohora SB. Hepatoprotective activity of *Solanum nigrum* fruits. *Fitoterap*.1997;LXVIII: 245-251.
3. Nedialkova ZK, Nedialkov PT, Nikolov SD. The genus *Chenopodium*: Phytochemistry, Ethno pharmacology and Pharmacology. *Phcog Rev*.2009;3(6):280-306.
4. Anonymous. *The Wealth of India (Raw Materials)*, Vol. 3, New Delhi: Publication and Information Directorate, CSIR; 2001;p464-469.
5. Warriar PK. *Indian Medicinal Plants- A Compendium of 500 Species*, Vol. 2, Chennai: Orient Longman Pvt Ltd; 2001;p.61-62.
6. Agarwal SS, Yamrekar BP, Paridhavi M. *Clinical Useful Herbal Drug*, New Delhi: Ahuja Publishing House; 2005;p.10-12.
7. Panda H. *Handbook on Medicinal Herbs with Uses*. New Delhi: Asia Pacific Business Press; 2005;p.325-26.
8. Pramila K, Neetu S, Anju R. Medicinal plants used in traditional health care system prevalent in Western Himalaya. *Indian J Traditional Knowled*. 2006;5(3):300-309.
9. Khare CP. *Indian Medicinal Plants*, New Delhi: Springer International Publication; 2007;p141-42.
10. Rastogi RP, Mehrotra BN. *Compendium of Indian Medicinal Plants*, Vol. 3, reprint edn. Lucknow: CDRI; 1998;p.162-63.
11. Della Greca M, D'Abrosca B, Fiorentino A, Previtera H, Zarrelli A. Structure elucidation and phytotoxicity of ecdysteroids from *Chenopodium album*. *Chem Biodivers*. 2005;2(4):457-62.
12. Della Greca M, Di Marino C, Zarrelli A, D'Abrosca B. Isolation and phytotoxicity of apocarotenoids from *Chenopodium album*. *J Nat Prod*. 2004;67(9):1492-5.
13. Cuttillo F, D'Abrosca B, Della Greca M, Zarrelli A. Chenoalbicin, a novel cinnamic acid amide

- alkaloid from *Chenopodium album*. *Chem Biodivers.* 2004;1(10):1579-83.
14. Cutillo F, Della Greca M, Gionti M, Previtera H, Zarrelli A. Phenol and lignans from *Chenopodium album*. *Phytochemical Anal.* 2006;17(5):344-9.
 15. Jhade D, Padmaa MP, Usha G. Isolation of phytoconstituents from the leaves of *Chenopodium album* Linn. *Journal of Pharmacy Res.* 2009;2(7):1192-1193.
 16. Dai Y, Ye WC, Wang ZT, Mastuda H, Kubo M, But PP. Antipruritic and antinociceptive effect of *Chenopodium album* L in mice. *J Ethnopharmacol.* 2002;81(2):245-50.
 17. Jabbar A, Zaman MA, Labal Z, Yaseen M, Shamin A. Anthelmintic activity of *Chenopodium album* L and *Caesalpinia crista* L against trichostrongylid nematodes of sheep. *J Ethnopharmacol.* 2007;114(1):86-91.
 18. Kumar S, Biswas S, Mandal D, Roy HN, Chakraborty S, Kabir SN. *Chenopodium album* seed extract: a potent sperm immobilizing agent both in vivo and in vitro. *Contraception.* 2007;75(1):71-8.
 19. Vijay N, Padmaa MP. Antibacterial activity of aerial parts of *Chenopodium album* Linn. *Journal of Pharmaceutical Research and Clinical Practice,* 2011;3(1):167-89.
 20. Vijay N, Padmaa MP. Anti-ulcer Effect of *Chenopodium album* Linn. against gastric ulcers in rats. *International Journal of Pharmaceutical Sciences and Drug Res.* 2011;3(4):319-322.
 21. Vijay N, Padmaa MP. Hepatoprotective activity of *Chenopodium album* Linn. against paracetamol induced liver damage. *Pharmacologyonline* 2011;3:312-328.
 22. Gujrati V, Patel N, Rao VN, Nandkumar K, Gouda TS, Shalam M, Kumar S. Hepatoprotective activity of alcoholic and aqueous extracts of leaves of *Tylophora indica* (Linn.) in rats. *Indian J Pharmacol.* 2007;38(1):43-47.
 23. Vogel WH, Scholkens BA, Sandow J, Muller G. *Drug Discovery and Evaluation; Pharmacological Assay.* Second ed. Berlin: Springer-Verlag; 2002;p.906-944.
 24. Amin A, Nanji MD, Samuel W, French MD. *Animal Models of Alcoholic Liver Disease—Focus on the Intra-gastric Feeding Model.* *Alcohol Research and Health.* 2003;27(4):325-330.
 25. Prajapati ND, Purohit SS, Sharma AK, Kumar T. *A Handbook of Medicinal Plant.* Jodhpur: Agrobios; 2003;p.203-15.
 26. Fromenty B, Pessayre D. Impaired mitochondrial function in microvesicular steatosis. Effect of drugs, ethanol, hormones and cytokines. *J Hepatol.* 1997;26:43-53.
 27. McClain CJ, Kromhout JP. Protection of acetaminophen hepatotoxicity by alcohol. *JAMA.* 1980;244:251-3.
 28. Seeff LB, Adler E. Acetaminophen hepatotoxicity in alcoholics. A therapeutic misadventure. *Ann Int Med.* 1986;104:399-404.
 29. Fattah MA, Hasan AGA, Hamamy MI, Essam AS. Antioxidant and hepatoprotective activity of *Eucalyptus maculata*. *Med Sci Monit.* 2005;11:426-31.
 30. Kinjo J, Hitoshi M, Tsuchihashi R, Korematsu Y, Miyakoshi M, Murakami M, et al. Hepatoprotective constituents in plants 15: protective effects of natural-occurring flavonoids and miscellaneous phenolic compounds as determined in a HepG2 cell cytotoxicity assay. *J Nat Med.* 2005;23:36-41.