

Wound Healing Evaluation of Some Herbal Formulations Containing *Curcuma Longa* and *Cynodon Dactylon* Extract

V. M. Thakare*, R. Y. Chaudhari, V.R. Patil

*Corresponding author:

Vinod M. Thakare

1. TVES's Hon'ble Loksevak
Madhukarrao Chaudhari, College
of Pharmacy, Faizpur, Tq: Yawal,
Dist: Jalgaon. Pin:425503

Abstract

The wound healing effect of herbal cream formulated with *Curcuma longa*, and *Cynodon dactylon* embedded in different ointment bases (anionic, cationic and non-ionic) has been evaluated *in vivo* using the incision, excision and dead space tissue wound models, on Swiss wister rat. *Curcuma longa*, and *Cynodon dactylon* was extracted using Pet ether (60-80⁰C), chloroform, ethanol, methanol and water. The methanolic extract formulated as herbal preparations. The herbal preparations were used to treat wounds inflicted on experimental Swiss wister rat. The wound healing effects of the formulations were compared to that of a standard antibiotic. In all cases, there was a progressive decrease in wound area with time, indicating an efficacy of the formulations in healing the induced wounds. By the 16th day, the formulation containing 100 mg/g of *Curcuma longa*, and *Cynodon dactylon* in cationic base showed 100 % healing. The wound areas in the animals treated with the standard antibiotic, showed a 100% healing by the 17th day, indicating that the plant extract, at that given concentration, had a better wound healing property.

Keywords: *Curcuma longa*; *Cynodon dactylon*, Dead space wound, Incision, Excision.

Introduction

Wound healing is an important biological process involving tissue repair and regeneration. A wound is described as 'a break in the continuity of tissue, from violence or trauma' and is regarded as healed if there is a restoration of the wounded or inflamed tissue to normal condition[1]. Wound healing can be classified into any of three types – healing by first intention, healing by second intention or healing by third intention, depending on the nature of the edges of the healed wounds. In wounds healed by the first intention, the edges are smoothly closed

that no scar is left. On the other hand, wound healing by second intention involves formation of granulation tissues which fill up the gaps between the wound edges and is associated with significant loss of tissue, leaving little scars. Wounds healed by third intention, are usually those left open for three to five days until granulation bed falls before they are sutured, generally resulting in extensive scar formation[2]. There are four distinct stages involved in wound healing namely – inflammatory stage, debridement stage, proliferation stage and maturation/remodeling stage. When an injury occurs, the vascular integrity of the injured area is disrupted leading to extravasations of blood into

the surrounding tissue or plasma when the damage is minor. The inflammatory stage is directed at preventing further loss of blood by platelet adhesion/accumulation at the site leading to coagulation that results to the formation of thrombus. The debridement stage occurs from the third to the sixth day after injury and involves the appearance of neutrophils to clear contaminating organisms. The characterized by endothelial budding in the nearby blood vessels forming new capillaries that penetrate and nourish the injured tissue. The maturation stage commences from the tenth day to several months depending on wound severity during which the number of capillaries decreases and wound changes from pink to white [2]. Certain factors that influence wound healing include bacterial infection, nutritional deficiency, drugs, sterility, obesity, movement of wound edges, site of wound, and wasting diseases [3]. The wound healing activities of plants have since been explored in folklore. The significant successes recorded have led to investigation into medicinal plants with a view to confirming these acclaimed properties. Records have it that different parts of plants used for wound healing contain some active principles or components that are antimicrobial [4] and nutritive in function. However "Mother nature" has been kind to us by creating various herbs which assist in the healing process. This treatment provides fibrogenetic and concentration of collagen resulting in faster healing. The drugs selected for this work are *Cynodon dactylon*, *Curcuma longa*. The plant occupies a renowned position in ayurveda, unani and homoeopathic systems of medicine [5]. Antidiabetic [6], antioxidant [7-10], antimicrobial [11-14], antiplaque [15] wound healing [16-18] activities of the plant are earlier reported. These two important herbs are reported to have significant anti-bacterial activity, which are complementary to wound healing process. The growing popularity of natural and herbal medications, easy availability of raw materials, cost-effectiveness and paucity of reported adverse reaction, prompted us formulate a polyherbal topical preparation and assess its wound healing

ability. The combination is used in order to enhance the wound healing activity.

Materials and methods

Materials

The herbs *Curcuma longa* and *Cynodon dactylon* were obtained from local habitat of the Faizpur, North Maharashtra, India and were identified in the Department of Botany, R T M University Nagpur, India where a Voucher specimen was also deposited. Shea butter, liquid paraffin and white soft paraffin were obtained from market having analytical grades and include anionic emulsifying wax, cetrimide, Cetostearyl alcohol, Tween 65 EP, from local market and were used as it is.

Preparation of extract

The rhizomes and whole plant *Curcuma longa* and *Cynodon dactylon* respectively were washed, then dried and ground into powder by pulverized. These materials were separately charge in soxhlet apparatus with Pet ether (60-80⁰), Chloroform, Ethanol, Methanol and Water. The mixture was filtered and the filtrate placed in a hot air oven maintained at 40⁰C. After evaporation of the solvent, the resulting extract was placed in a sealed bottle in freeze until ready for use.

Formulation of emulsifying ointments

Three different emulsifying ointments representing anionic, cationic and non-ionic types respectively, were prepared according to the table no 1.

In preparing the anionic emulsifying ointment, the liquid paraffin, white soft paraffin and emulsifying wax were melted together in a beaker and immersed in a thermo stated hot water bath. The melted ingredients were stirred until cold. For the cationic and non-ionic emulsifying ointments, the cetostearyl alcohol and shea butter were melted at about 97⁰C, followed by the addition of cetrimide or Tween 65 as the case may be, and stirring continuously till cold.

Table no 1 : Formulation of emulsifying ointments

Material	Anionic emulsifying ointment	Cationic Emulsifying ointment	Non-Ionic Emulsifying ointment
Shea butter	-	50%	60%
Cetostearyl alcohol	-	42%	36%
Tween 65 EP	-	-	4%
Cetrimide	-	5%	-
Emulsifying wax BP	28%	-	-
Liquid paraffin	21%	-	-
White soft paraffin	51%	-	-

Table no 2 : Formula for medicated ointment

Formulation	Anionic %	Cationic %	Non ionic %
Anionic emulsifying ointment	90%	-	-
Cationic emulsifying ointment	-	90%	-
Non-ionic emulsifying ointment	-	-	90%
<i>Curcuma longa and Cynodon dactylon methanolic extract</i>	10%	10%	10%

Preparation of medicated ointments

The medicated ointments were prepared according to the following formula: showed in table no 2.

The fusion method was employed in the preparation of the medicated ointments. The required quantity of the ointment base was weighed and melted at a temperature of about 70°C in a hot water bath. The designated quantities of extract/s were respectively added to the melted base at 40°C and the mix, stirred gently and continuously until a homogenous dispersion is obtained.

Animal studies:

Healthy Swiss Wistar Rat were employed in the study albino wistar rats (150-200 g) were obtained from the animal house of the Department of Pharmacology College of Pharmacy, Faizpur, India. The registration number and date of registration was 652/02/a/CPCSEA 19/07/2002. The animals were placed in six groups (n = 6) for the studies. They were allowed to acclimatize in the research laboratory for 4 days before the commencement of the study and were fed with standard livestock pellets. Animal house was well maintained under

standard hygienic conditions, at a temperature ($22 \pm 2^\circ\text{C}$), room humidity ($60\% \pm 10\%$) with 12 hours day and night cycle. The animals were allowed unrestricted access to clean drinking water. The animals were quarantined for a period of three weeks to ensure stabilization before use. Feeds and water provided for the animals *ad libitum*.

Preparation excision wound site

The wound site was prepared following the excision wound model. The animals were anaesthetized with diethyl ether and the hairs on the skin of the back, shaved with sterilized razor blades. A circle of diameter 20 mm was marked on each of the two sides of the skin. Circular incisions were then made on the marked areas of the skin surface and the skin carefully dissected out. The area was measured immediately by tracing out the wound area using a transparent tracing paper and the squares counted.

Wound healing studies

A round seal of 15 mm diameter was impressed on the sides of the central trunk depilated and sterilized with ethanol. Excision wound was inflicted on the rats according to methods described by Morton and Malone (1972) under light ether anaesthesia [19]. Full skin thickness was excised from the marked area to get a wound measuring about 177 mm^2 . After achieving complete haemostasis by blotting the wound with cotton swab soaked in warm saline, the animals were placed singly in individual cages. The wounds of the animals were treated topically depending on the group. Group 1, 2, 3 were treated with the ointment batches A, B, C containing of *Curcuma longa*, and *Cynodon dactylon* extract 100 mg/ 100 g of the ointment base. Group 4 was treated with the standard Framycetin Sulphate preparation (Batch D) while group 5 served as the negative control and was treated with the blank ointment formulation (Batch E). The wound area was measured with a

translucent paper and thereafter estimated on a 1 mm 2 graph sheet every days until epithelialization and complete wound closure was recorded. Wound contraction was calculated as a percentage of the original wound size.

Incision wound

In incision wound model, 6 cm long paravertebral incisions were made through the full thickness of the skin on either side of the vertebral column of the rat as described by Ehrlich and Hunt et al [20]. The wounds were closed with interrupted sutures of 1 cm apart. The animals were divided into six groups of six animals each. The formulations A,B,C were treated with 50 mg of ointment formulations prepared from *Curcuma longa* and *Cynodon dactylon* methanolic extracts and D treated with Framycetin Sulphate preparation while group 4 served as the negative control and was treated with the blank ointment formulation (Batch E). The ointment was topically applied once in a day. The sutures were removed on the 8th post wound day. The skin breaking strength of the wounds was measured on the 11th day as described in the method of Lee et al.[21].

Dead space wound

The animals were divided into eight groups of 6 rats in each group. Under light ether anaesthesia, dead space wounds were created by subcutaneous implantation of sterilized cylindrical grass piths (2.5 cm X 0.3 cm), one on either side of the dorsal paravertebral surface of the rat. The granulation tissues formed on the grass piths were excised on the 11th post wounding day and the breaking strength was measured. Simultaneously, granulation tissue so harvested was subjected to hydroxyproline estimation following the method of Woessner et al [22].

Table 3. Effect of formulation containing extract of *Cynodon dactylon* and *Curcuma longa* on Incision wound contraction

Group	Granuloma Strength (g)	Breaking Dry Granuloma weight (mg % of B.W.)	Hydroxyproline Content
Control /	279.89±1.60	45.08±2.38	6.89±0.44
Standard FSC/	401.23± 1.74	89.35 ±1.38	20.89± 0.57
Anaionic	326.69±1.15	65.88±1.90	9.97±0.45
Nonionic	337.58±1.45*	69.15±1.35	11.25±0.53
Cataionic	387.35±1.23*	84.12±1.23*	19.19±0.43*
One way Anova F	3.466	4.567	3.014

Values are mean ± S.E.M., * P<0.001 vs. control; n= 6.

Statistical analysis: The data were analyzed using one way analysis of variance (ANOVA) and data subjected to LSD post hoc test. Differences in mean between paired observations were accepted as significant at P≤0.05.

Results and Discussion

Table 3 for incision wound model shows the results of the wound healing effects of the various ointment formulations. There was a general decrease in wound area upon application of the ointments and with time. By the 4th day, the animals treated with ointments containing 100 mg/g of *Curcuma longa*, and *Cynodon dactylon* in anionic emulsifying ointment. There was however a hundred percent (100 %) healing in the animals treated with ointments containing 100 mg/g of *Curcuma longa*, and *Cynodon dactylon* in cationic emulsifying agent by the 16th day after treatment, as the wound sizes reduced to zero. The ointment containing the negative control had the least rate of wound healing. Hydroxyproline content in control group was least where as in standard and cationic ointment is maximum. The dry granuloma weight was showed in table no 3 which was comparable for standard to cationic ointment. The granuloma breaking strength was

maximum for standard Framycetin Sulphate ointment and for cationic ointment it was 387.35±1.23. The drug to be used for effective wound healing should be able to clear the wound by the 19th day after infliction. The infection on wound for the animals treated with the ointment containing 100 mg/g of anionic emulsifying could be attributed to contamination or adverse effect of the formulation.

The above result, presented in form of percentage wound size reduction is shown in Fig.No. 1-5 for incision wound. The fig. No. 6 shows the wound on 11 day for excision wound. The excision wound healing showed in fig. no 7 for 0 day, 06 day and 12 day. The ointments prepared with *Curcuma longa*, and *Cynodon dactylon* in cationic emulsifying ointment base exhibited the highest initial rate of wound healing. It was followed closely by the ointment prepared with non-ionic emulsifying ointment. The control ointment containing neither *Curcuma longa* and *Cynodon dactylon* extract nor drug had a very low initial healing rate. By the tenth day however, all the ointment formulations showed almost the same rate of wound healing with the exception of the control ointment which maintained a very slow rate of wound healing even up to the 19th day. The best activity was observed in the

ointment containing *Curcuma longa* and *Cynodon dactylon extract* in cationic ointment base. This shows that *Curcuma longa* and *Cynodon dactylon extract* can effectively be employed as a cationic emulsifying ointment in wound healing.

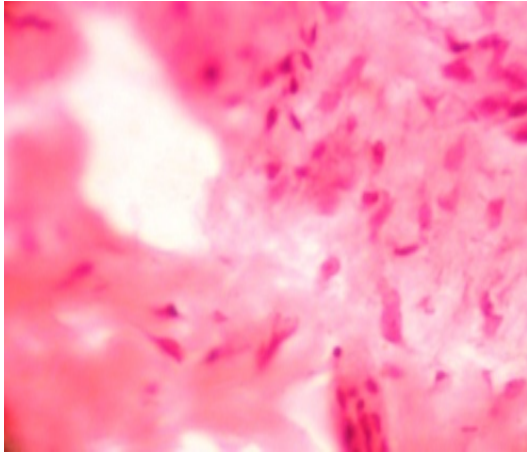


Fig No:1 Incision wound after 11 day for Control ointment

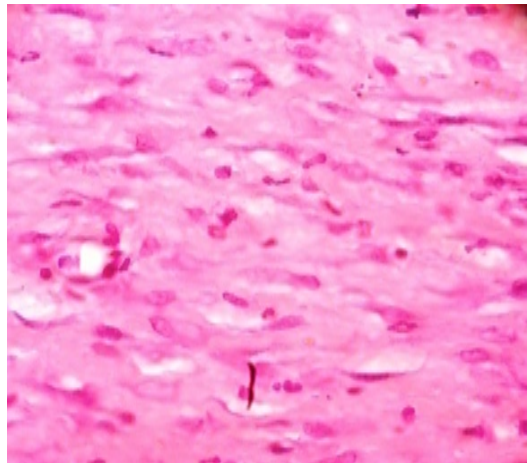


Fig No:2 Incision wound after 11 day for Cationic ointment

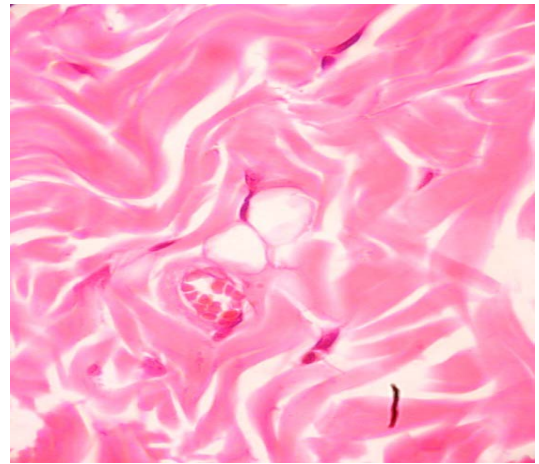


Fig No:3 Incision wound after 11 day for Anionic ointment

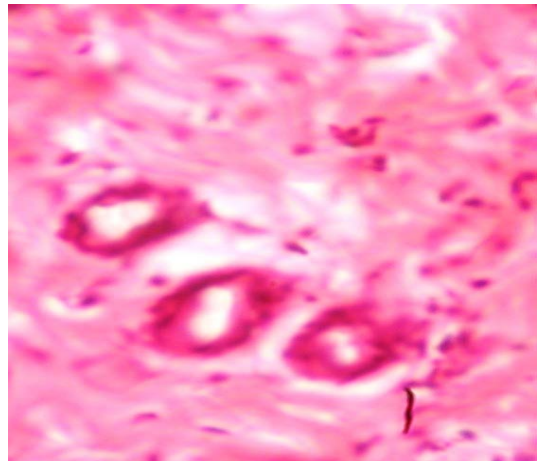


Fig No: 4 Incision wound after 11 day for Non ionic Ointment

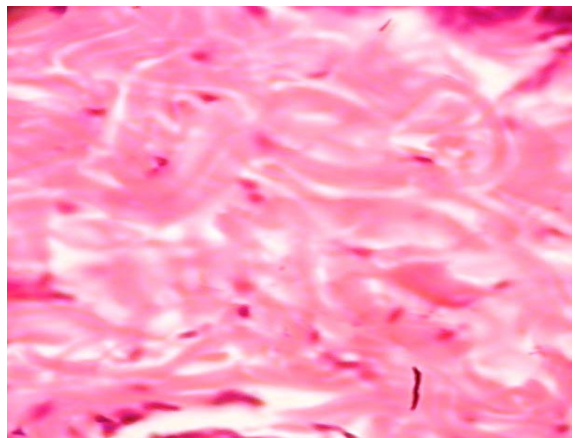


Fig No: 05 Excision wound after 11 day for standard drug

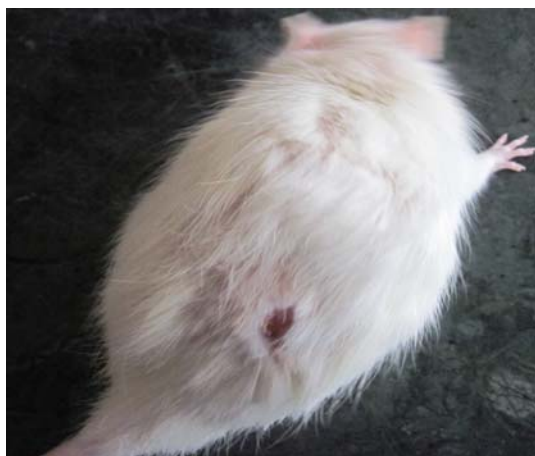

Fig No: 6 Incision wound after 11 day cationic ointment

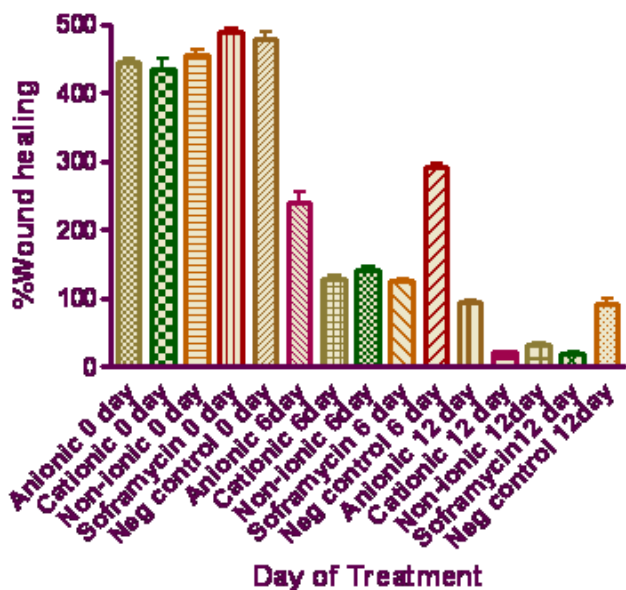


Fig no: 7 Effect of Formulation on excision Wound Model

Conclusively, the various ointments prepared with *Curcuma longa* and *Cynodon dactylon extract* exhibited a good wound healing effect comparable to those of Framycetin Sulphate, a standard antibiotic used in wound healing. This finding thus, justifies its use in folkloric medicine for wound healing.

Acknowledgment

Authors wish to thank Principal, T.V.E.S's Hon'ble Loksevak Madhukarrao Chaudhari, College of Pharmacy, Faizpur for providing the necessary facilities to carry out this work.

Declaration of interest

The authors report no conflicts of interest.

References

- [1]. Taber, CW. Taber's Cyclopedic Medical Dictionary, 10th edition, F. A. Davies Company, U. S. A. 1965.
- [2]. Thomas, J C., Veterinary Pathology, 6th edition, William's and Wilkin, Maryland, USA, 1997, pp. 150-156.
- [3]. Karl M., Lacrix J.V, Preston H.H. Canine surgery, 4th edition, American Veterinary Publications, California., 1995, pp 42-45.
- [4]. Ahmed, S., Reza, M.S., Haider, S.S., Jabbar, A., Antimicrobial activity of *Cynodon dactylon*. Fitoterapia., 1994,65, 463-464.
- [5]. Balachandran P., Govindarajan R., Ayurvedic drug discovery, Expert Opinion Drug Dis., 2007, 2 (12),1631-1652.
- [6]. Jarald, E.E., Joshi S.B., Jain D.C., Antidiabetic activity of aqueous extract and non polysaccharide fraction of *Cynodon dactylon* Pers. Ind J Exp Bio., 2008,46: 660-667.
- [7]. Santhi R., Kalaiselvi K., Annapoorani S., Antioxidant efficacy of *Cynodon dactylon* leaf protein against ELA implanted swiss albino mice, J Pharm Res 2010, 3(2),228-230.
- [8]. Saradha Devi K. M, Annapoorani S. Ashokkumar K., Hepatic antioxidative potential of ethyl acetate fraction of

- Cynodon dactylon* in Balb/c mice, J Med Plants Res., 2011,5(6), pp. 992-996.
- [9]. Govindarajan, R., Vijayakumar, M., Pushpangadan, P., Antioxidant approach to disease management and the role of 'Rasayana' herbs of Ayurveda. J Ethnopharmacol., 2005,99, 165–178.
- [10]. Auddy, B., Ferreira, M., Blasina, F., Lafon, L., Arredondo, F., Dajas, F., Tripathi, P.C., Seal, T., Mukherjee, B., Screening of antioxidant activity of 3 Indian medicinal plants, traditionally used for the management of neurodegenerative diseases. J Ethnopharmacol., 2003,84, 131–138.
- [11]. Surh Y.J, Anti-tumor promoting potential of selected spice ingredients with antioxidative and anti-inflammatory activities—a short review. Food and Chemical Toxicology., 2002, 40, 1091-1097.
- [12]. Iyengar M.A., Pattabhi M., Rao R., Anti-microbial activity of the essential oils of *Curcuma longa* leaves. Ind Drugs., 1995, 32 (6),249-250.
- [13]. Chandic R., Dash S.K., Mishra R.K., Anti E. coli activity of Turmeric essential oil. Ind Drugs., 2001, 38 (3): 106-111.
- [14]. Artizzu, N., Bonsignore, L., Cottiglia, F., Loy, G., Studies on the diuretic and antimicrobial activity of *Cynodon dactylon* essential oil. Fitoterapia., 1996,67, 174–176.
- [15]. Raveendra Pai M., Acharya L.D., Udupa N., Evaluation of antiplaque activity of *Curcuma longa* leaf extract gel a 6-week clinical study. J Ethnopharmacol., 2004, 90,99-103.
- [16]. Subramanian, S., Nagarajan, S., Wound healing activity of *Pongamia pinnata* and *Cynodon dactylon*. Fitoterapia., 1988,59, 43–44.
- [17]. Thakare V.M., Chaudhari R.Y, Patil V.R., Promotion of cutaneous wound healing by herbal formulation containing *Azadirachta indica* and *Cynodon dactylon* extract in wistar rats, Int J Pharm Res Dev., 2011,3(4), 80 – 86.
- [18]. Thaker A.M, Anjaria J.V., Anti-microbial and infected wound healing response of some traditional drugs. Ind. J. Pharm., 1985, 18:171-174.
- [19]. Morton J.J.P., Malone M.H., Evaluation of vulnerary activity by an open wound procedure in rats. Arch.Int. Pharmacodyn., 1972, 196,117-126.
- [20]. Ehrlich P.H., Thomas K. H., Effects of Cortisone and vitamin A on wound healing, Annals of Surg., 1968,168,3,324-328.
- [21]. Lee, K.H., Krei, C.H, Studies on the mechanism of action of salicylate retardation of wound healing by aspirin, J Pharm. Sci., 1968, 57, 1042-1043.
- [22]. Woessner J. F, Jr., Determination of hydroxyproline in tissues and protein samples containing small proportion of this amino acid, Arch Biochem Biophys. 1961,93, 440-447.